



## Multi Radiance for Companion

Case study from Lola

May – July 2024



# Anamneses – Lola – May, 28th 2024



**Lola**, is a 15- and 6-months old female west highland white terrier.

Lola has been grown up in Canada, then moved to the US and now she is living with her owners for 1 year in Switzerland. Lola is a lively dog with good temper despite all the health problems she has.

## **Physical health situation :**

- **Chronic allergies** (race predisposition)
- **Osteoarthritis** in the left hip, Symptoms: lameness, compensation by right hind leg
- **Pain on the scale from 1-10:** greater than 5
- **Lick granulomas:** on the belly with small size – below 0.5 cm
- **Swellings from former hot spots:** in August 2023 Lola had hotspots which slowly healed, but left a big swellings
- **Left side of head:** Otitis, eye secretion, congestion of the left nose
- **Lips:** The lips are for two years often crusty, and underneath swollen with inflamed skin / mucosa which is bleeding sometimes
- **Medication in the past:** Antibiotics
- **Current medication:** Immunosuppressive drugs
- **Current supplements:** None (Due to expected deficiency symptoms and due to the diet food to reduce the allergies, the addition of collagen was recommended)

..

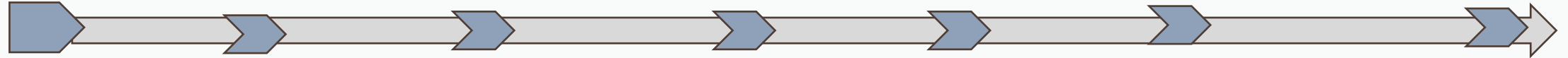
# Lola – Treatment with Multi Radiance Laser



The treatments followed the holistic approach and the priority principles from Multi Radiance.

- The treatment focused on the major problems first.
- Treatment started on May 28<sup>th</sup>, 2024 with the super pulsed MR5 ACTIVet Pro laser.
- As treatments used inhibitory and stimulatory frequencies the treatments were whenever possible performed twice per day (mornings and evenings).
- The phases are reflecting the priority principle. Example: As long as inflammation is present, you should treat it first. This is meant with the different phases. Once the inflammation is (significantly reduced), you can transition to Tissue Repair.

Treatment was started for pain relief, osteo-arthritis in the hip, lick granulomas, swellings from hot spots and **otitis**:



## 28<sup>th</sup> May 2024

- Unwind
- Inflammation for Osteoarthritis
- **Otitis?**
- Several lick granulomas on belly
- Hot spots on chest

## 12<sup>th</sup> June 2024

- Break due to allergic reaction on wrong food

## 22<sup>nd</sup> June 2024

- Chronic inflammations on lips and nose
- New hot spots
- New lick granulomas

## 11<sup>th</sup> July 2024

- Screening with WellVu Thermal Imaging Imaging found arthritis in knee instead of hip
- Inflammation of belly due to arthritis compensation
- Swellings from former hot spots slightly visible
- Adaptation of Osteoarthritis treatment for knee instead of hip

## 24<sup>th</sup> July 2024

- Break due to allergic reaction on wrong food

## 29<sup>th</sup> July 2024

- Wellness screening
- Osteoarthritis treatment shows success
- Inflammation almost gone
- Swellings from former hot spots not visible anylonger

## 30<sup>th</sup> July 2024

End of case description and continuation of laser treatments


# Lola – Indication 1 - Osteoarthritis



## 1. Osteoarthritis:

- **Symptoms:** Lola appeared to have pain from the arthritis in her right hip
- **Treatment with Pain Relief:** the Unwind protocol was used for relaxation and relief with the scan technique in 1'000 Hz for approx. 5 minutes.
- **Treatment for Inflammation** after a break of 4 hours with 50 Hz for reducing inflammation in the joints and along the joint line.
- **Treatment for Tissue Repair** with 250 Hz once the inflammation is significantly reduced.
- **Treatment for Photohemotherapy (PHT)** with 50 Hz to increase the blood flow.

**May 28th 2024 – before treatment started**





# Lola – Indication 1 - Osteoarthritis



## 1. Osteoarthritis:

- Treatment started on May 28<sup>th</sup>.

**June, 2nd 2024 – after 5 treatments  
Right leg only faltered once**



**June, 8th 2024 – after 8 treatments  
Right leg only faltered once**



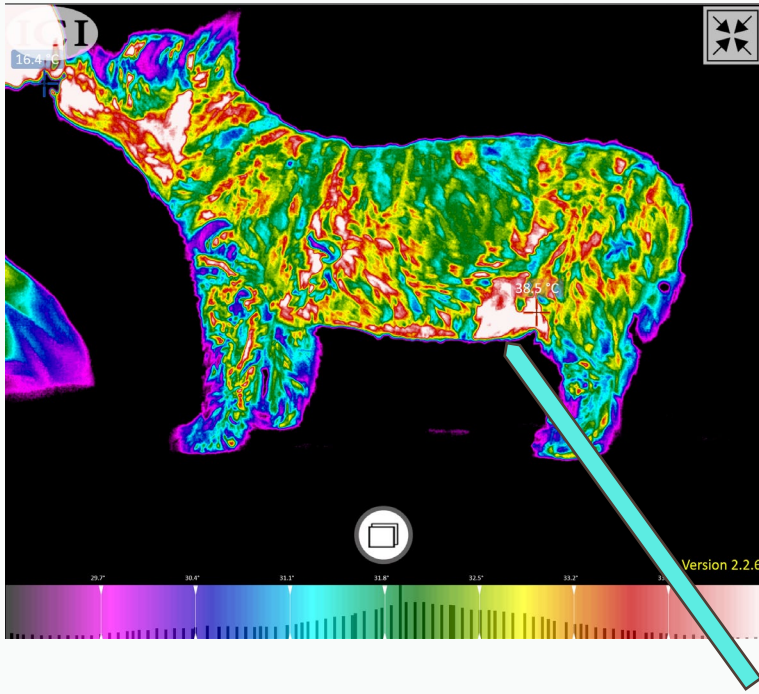
# Lola – Indication 1 - Osteoarthritis



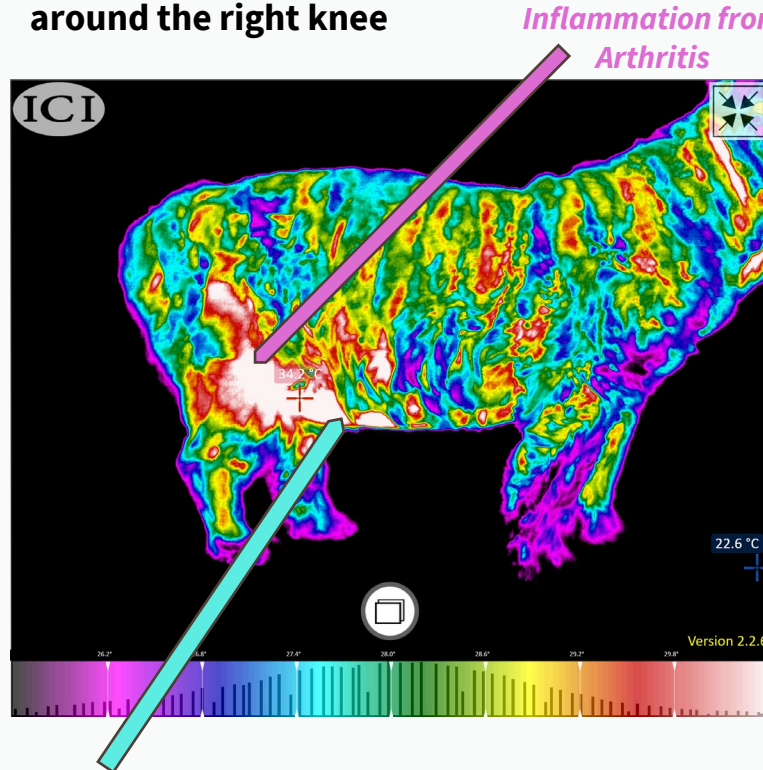
## 1. Osteoarthritis:

- After a WellVu examen, it was found that the osteoarthritis is in the knee, not in the hip.
- Treatment location was adapted (after break due to inflammation of the gastrointestinal tract) from 11th July 2024 onwards.

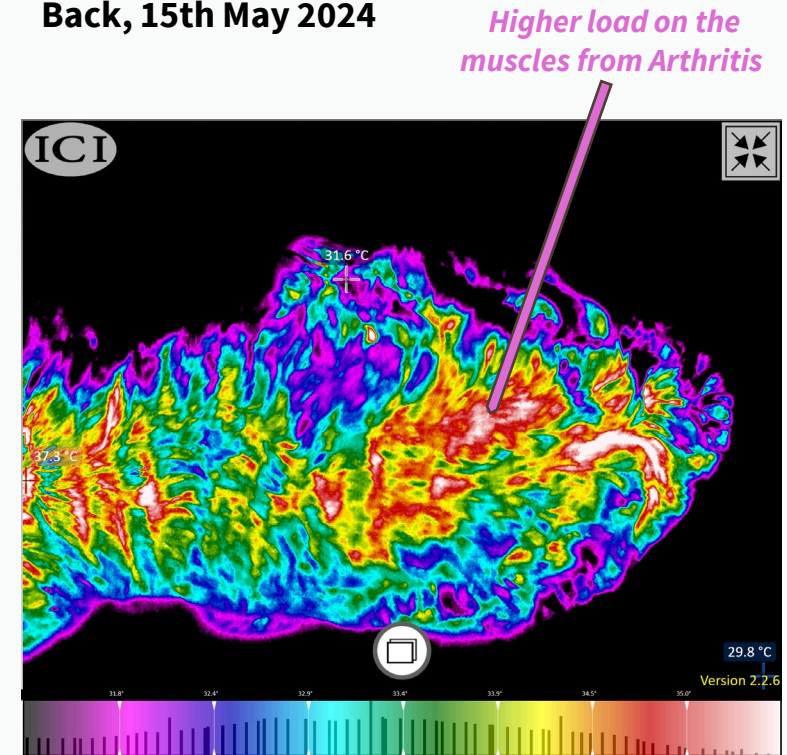
July, 15th 2024 - Left knee



July, 15th 2024 - Arthritis is mainly around the right knee



Back, 15th May 2024





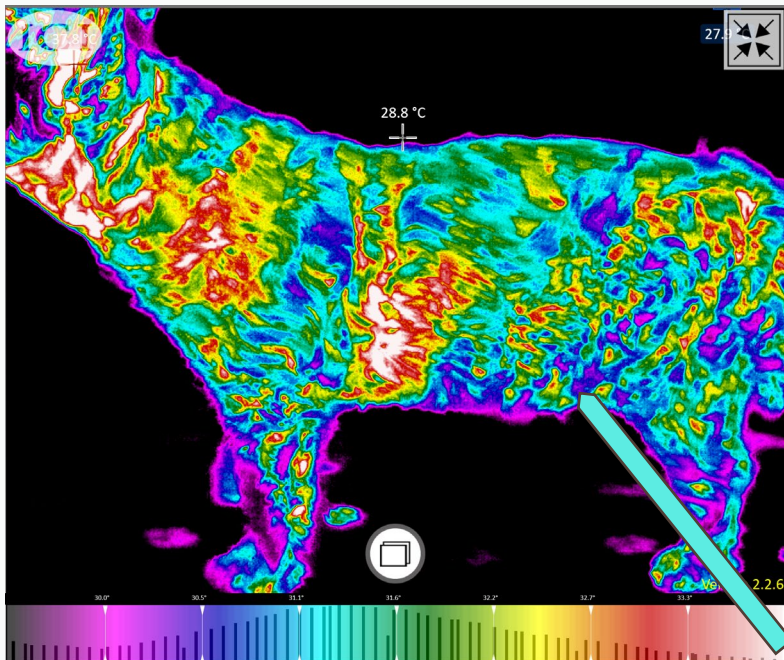
# Lola – Indication 1 - Osteoarthritis



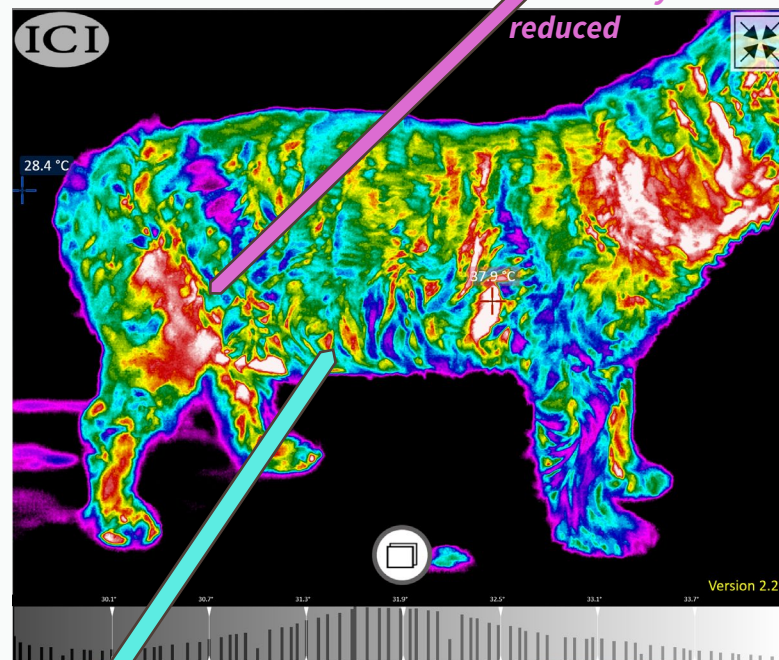
## 1. Osteoarthritis:

- After a WellVu examen, it was found that the osteoarthritis is in the knee, not in the hip.
- Treatment location was adapted (after break due to inflammation of the gastrointestinal tract) from July onwards.

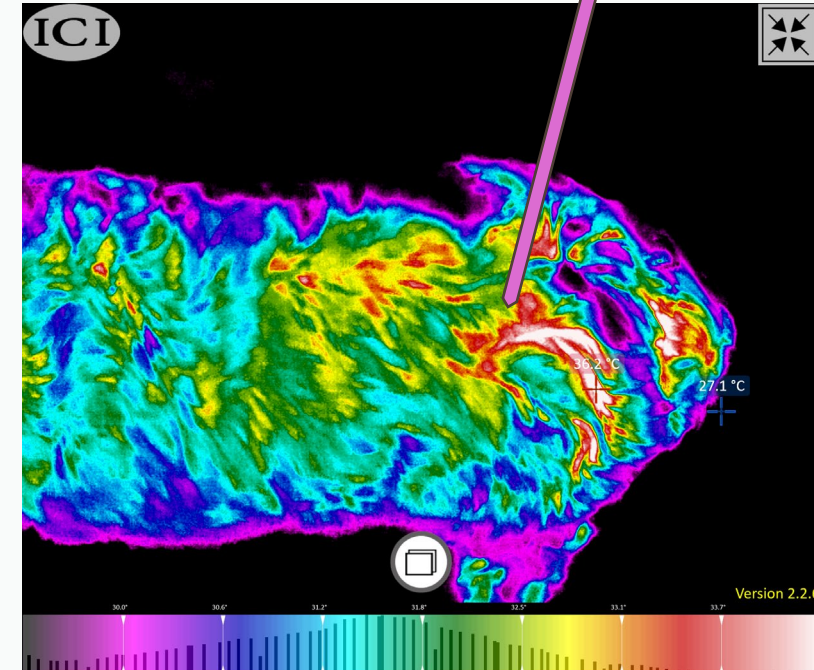
July, 29th 2024 – Left knee



July, 29th 2024 – Arthritis is mainly around the right knee



July, 29th 2024 – Back



*Inflamation from higher load on the muscles and allergic reactions significantly reduced due to laser treatments*



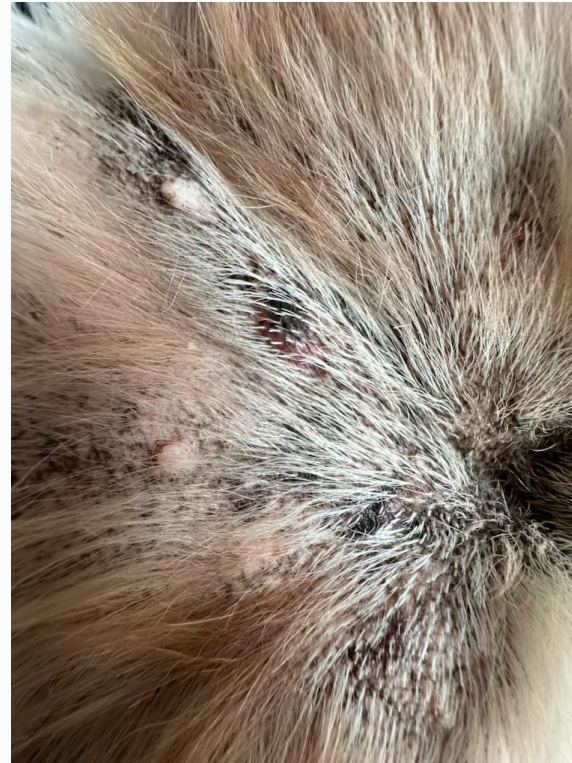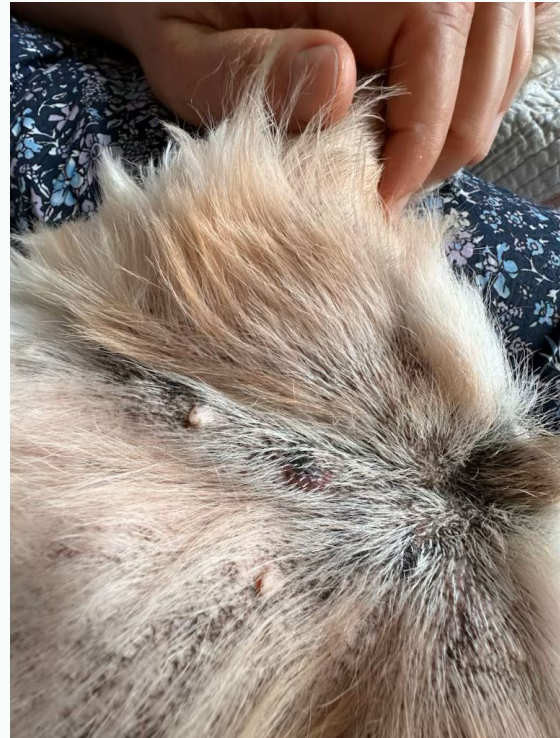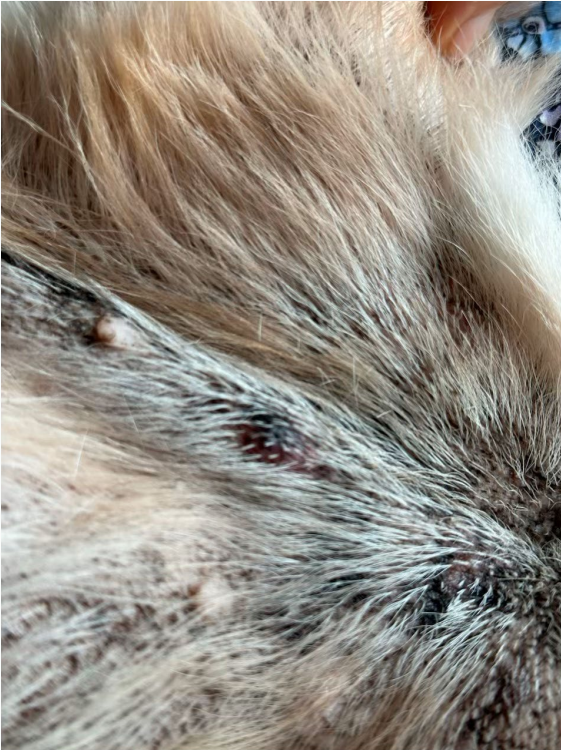# Lola – Indication 2 – Lick granulomas



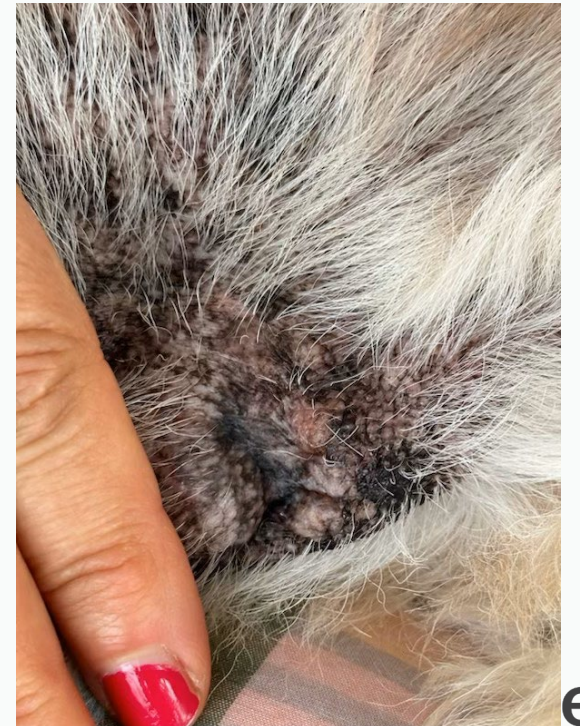## 2. Lick granulomas

- **Symptoms:** Small lick granulomas keep on popping up every week, they are treated with the following protocols:
- **Treatment with inflammation protocol: 50Hz with additional blue light for 1 to 2 minutes using scan technique:**
- **Treatment with tissue repair: 250Hz for 2 minutes in scan or direct contact technique:** Once per day, do not overtreat
- **Result:** Lick granulomas disappear after 3 treatments with Blue light

**1st lick granuloma, May 28th 2024 – treated three times**



**3rd lick granuloma, 22nd June 2024**





# Lola – Indication 3 – Hot spots on Chest - 1

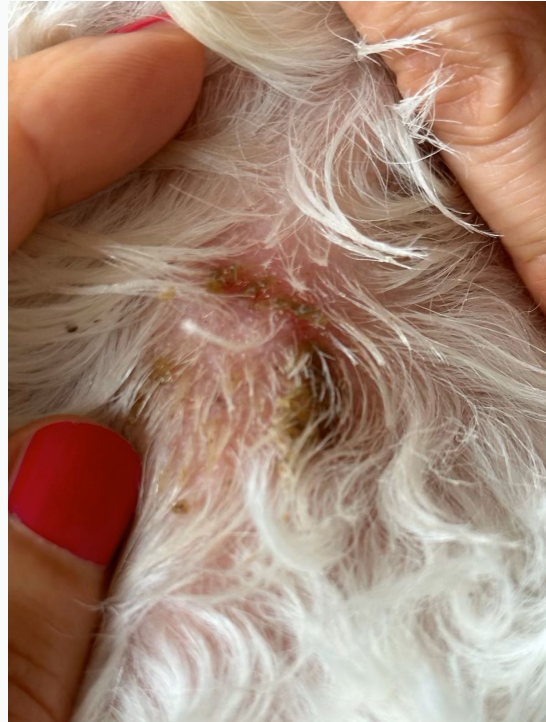
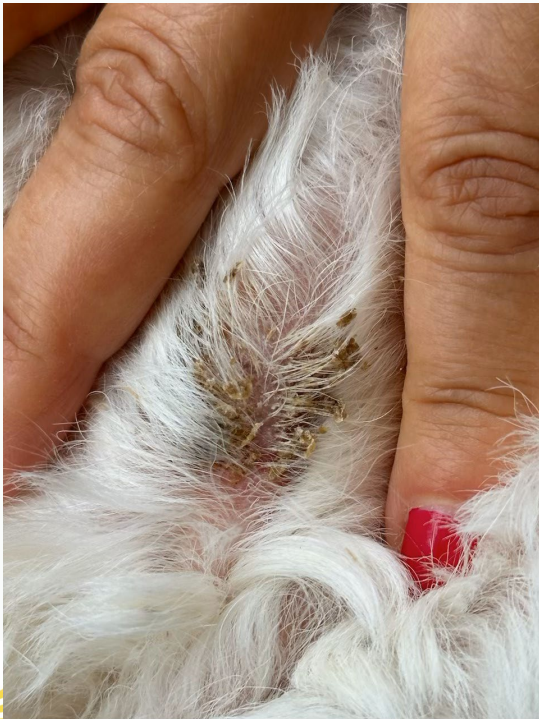
## 3. Hot spots

- **Symptoms:** Small hot spots keep on popping up every week, they are treated with the following protocols:
- **Treatment for inflammation:** Blue light for 5 minutes and 50Hz for 1 to 2 minutes using scan technique
- **Treatment for tissue repair after inflammation was subsided:** 250Hz for 2 minutes in scan or direct contact technique: Once per day, do not overtreat

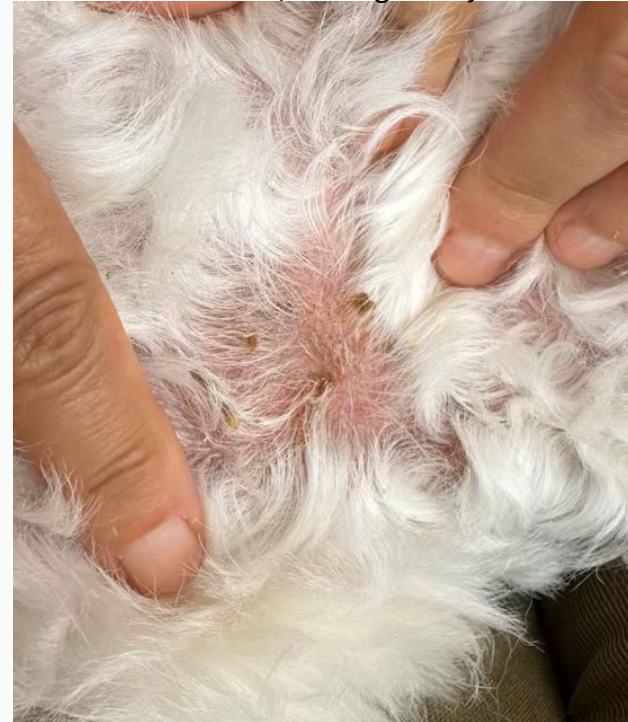**Result:** Hot spots disappeared after 6 treatments, 3x blue light and 3x 250Hz

## 2nd hot spot, June 2024 – before and after cleaning



## 2nd hot spot, June 2024 – 30th June

After 5 treatments, blue light only for around 3 times and 50Hz with blue light



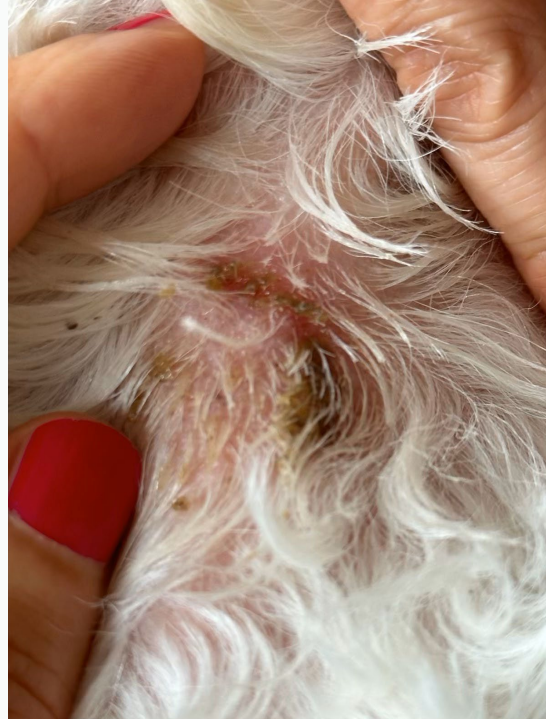
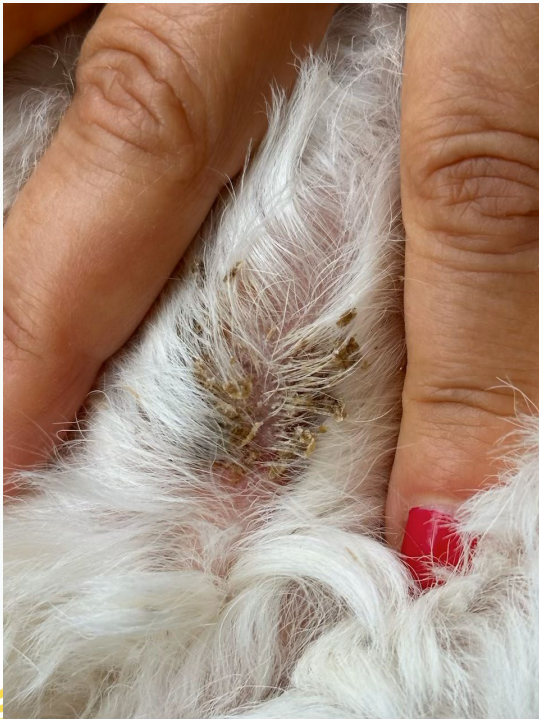
# Lola – Indication 3 – Hot spots on Chest - 2



## 3. Hot spots

**2nd hot spot, June 2024 – before and after cleaning**



**3rd hot spot, 8th July 2024**



After 6 treatments, 3x blue light and 3x 250Hz





# Lola – Indication 3 - Otitis



## 4. Otitis on left ear

The ear canal is swollen, no infection.

- Same treatment as for the lick granulomas, number of sessions / bouts: 10 to 14 until the swelling has gone.
- Make sure that the ears are gently cleaned, if necessary, before the treatment starts.
- **Remark:** the Otitis comes together with congestion of the left part of the nose and swollen, secreting left eye -> potentially **Horner syndrome**

# Lola - Indication 4 - Swelling from hot spots - 1



## 4. Swelling from former hot spots

**Symptoms:** Lola had hot spots in August 2023 and in June 2024 three large swollen areas were still visible directly above her tail.

**Hot spots in August 2023**



**September, 1st 2023**



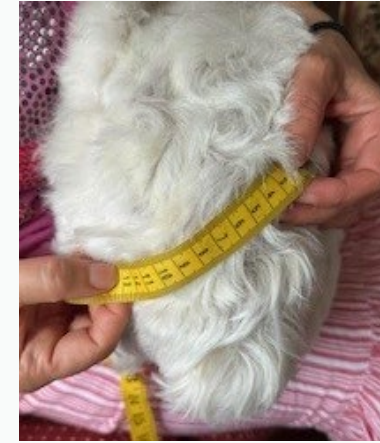**Middle hot spot, June, 1st 2024, 11.5cm wide, 3.5 cm deep**



**Hot spots in June, 1st 2024**



**Upper hot spot, June, 1st 2024, 13cm wide, 2.5 cm deep**



**Lower hot spot, June, 1st 2024 - 8cm wide, 4.5cm deep**

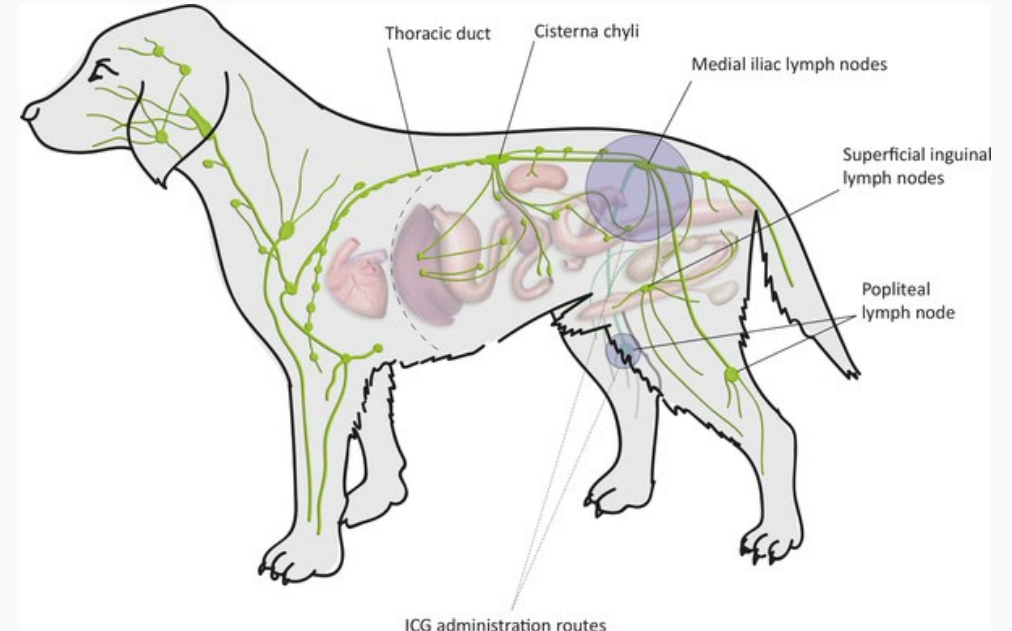
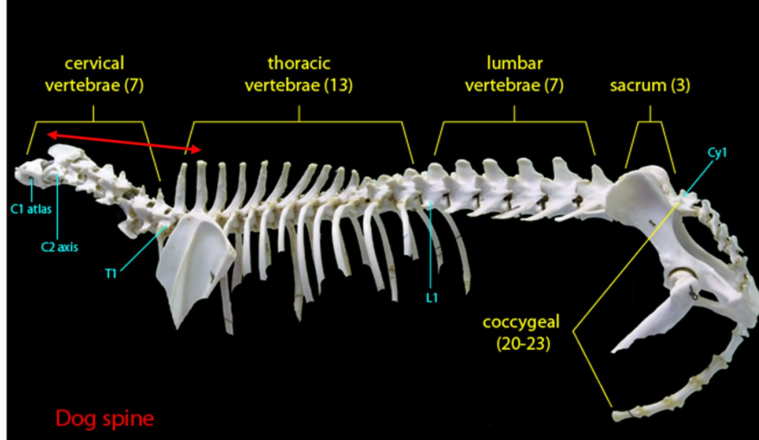




# Lola - Indication 4 - Swelling from hot spots - 2



- **Treatments:** The swellings were treated with the swelling protocol and additionally with photohemotherapy:
- **Treatment to reduce swelling 1000-3000Hz 3 minutes** - Using Oshiro's Method
- **Treatment to increase blood flow with photohemotherapy at 50 Hz** from T11 to L5, as well as the groin region for blood flow.

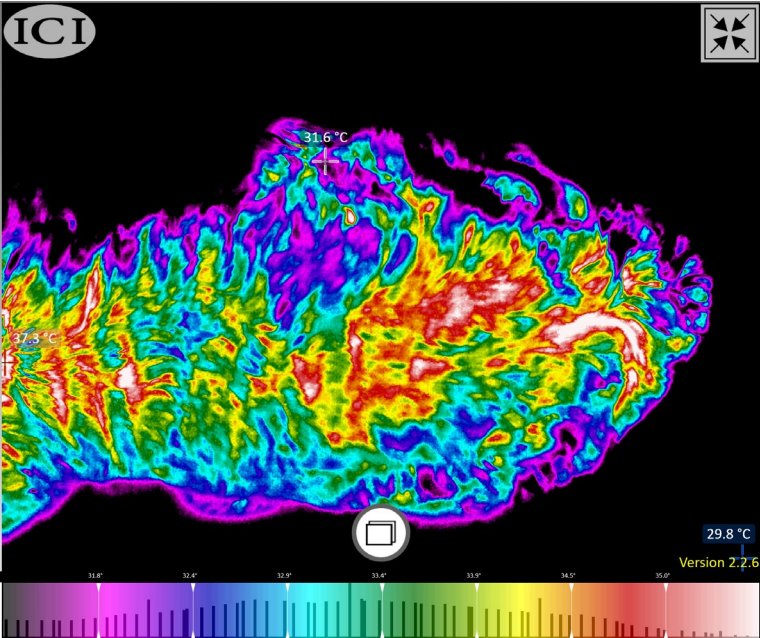


# Lola - Indication 4 - Swelling from hot spots - 3



## 4. Swelling from former Hot spots

Swelling on July, 15th 2024



Swelling on July, 15th 2024





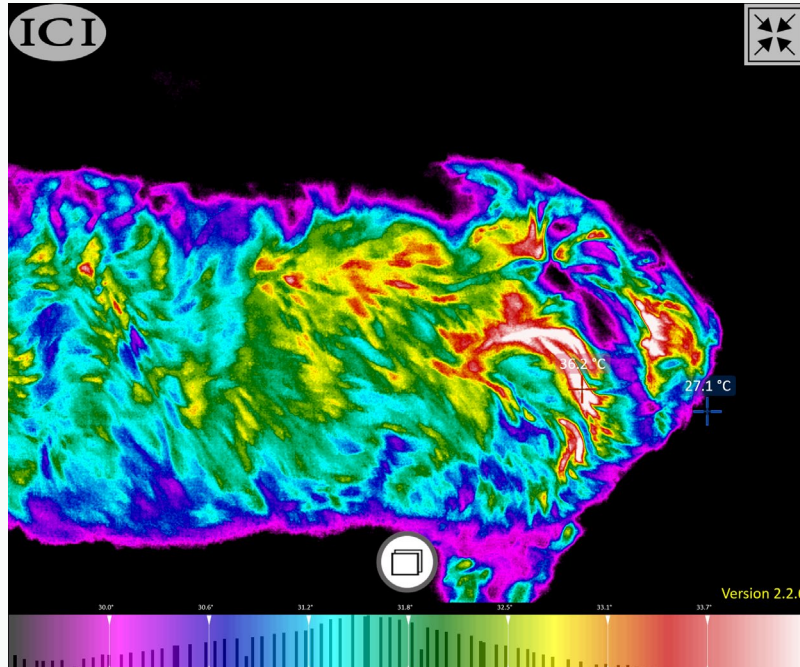
# Lola - Indication 4 - Swelling from hot spots - 4



## 4. Swelling from former Hot spots

- **Result:** swellings almost not visible any longer. Lola can also move her tail freely again

Swelling on July, 31st 2024



Swelling on July, 31st 2024



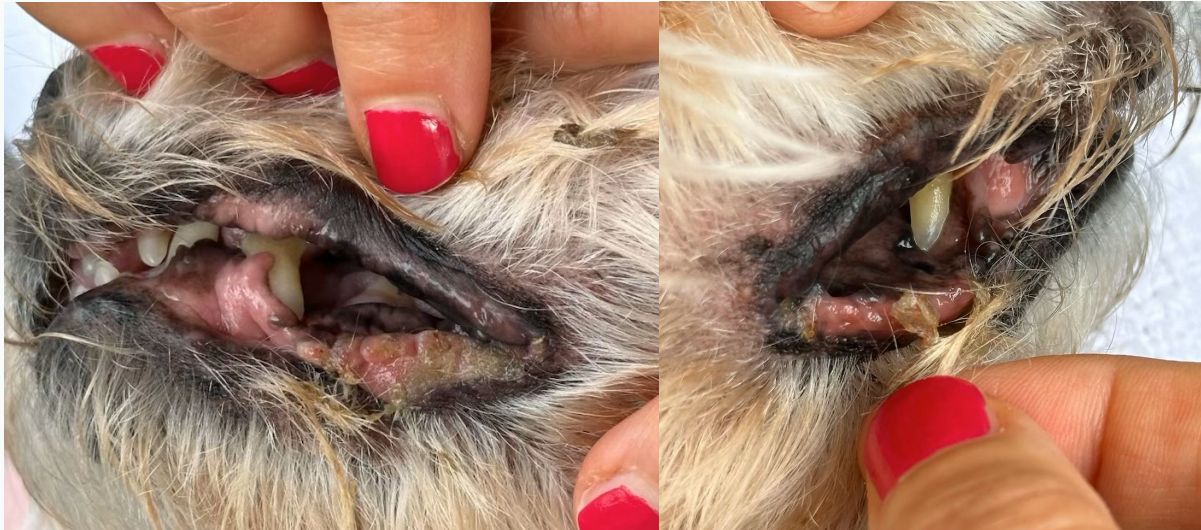# Lola – Indication 5 – Chronic inflammation



## 5. Chronic Inflammation on lips

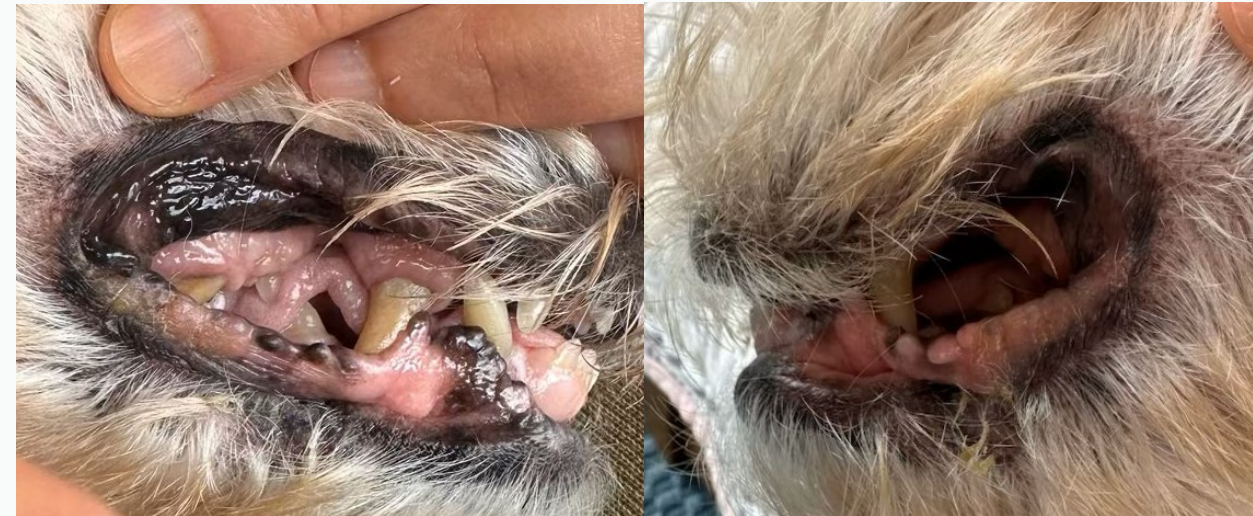- **Symptoms:** Lola's lips have been swelling and becoming inflamed for two years. The lips are crusted and the tissue under the crust is swollen, and the skin/mucous membrane is inflamed and sometimes bleeds..
- **Treatment with Blue light** for about 5 minutes.
- **Tissue Repair:** Once the bleeding was gone, 4-5 treatments with tissue repair protocol.

**Lips on 22nd June 2024**



**Lips on 30th June 2024**

After 6 treatments with blue light only for 5 minutes once per day!





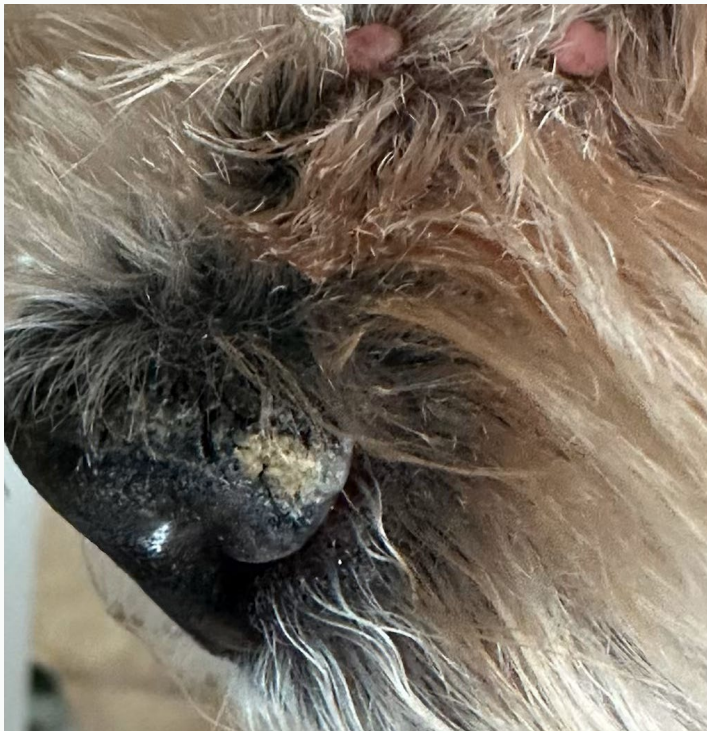# Lola – Indication 5 – Chronic inflammation



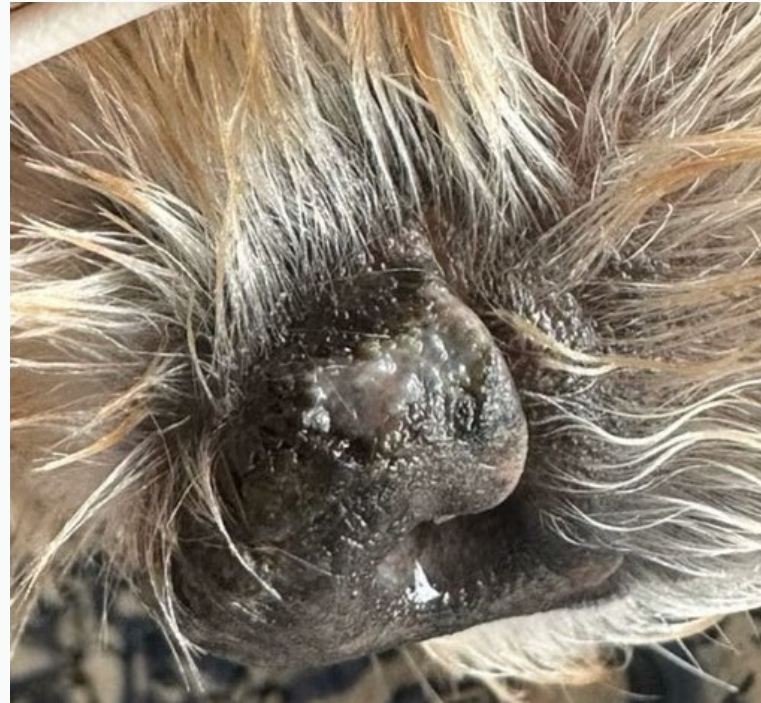## 5. Chronic Inflammation on nose

- **Symptoms:** the nose has crusty parts but is not bleeding.
- **Treatment with Blue Light** for about 5 minutes.
- **Treatment with Tissue Repair:** 4-5 treatments with tissue repair protocol.

Nose on 8th July 2024



Nose on 13th July 2024



# Summary and conclusion

Symptoms	Effects of laser treatments
<b>Dermatologic indications</b> <ul style="list-style-type: none"><li>• Due to the high allergy load, skin reactions such as hot spots and leakage granulomas often occur frequently.</li><li>• Due to immunosuppressive medication and antibiotics, further problems such as crusts on the mouth and nose occur, and the infections have persisted for about two years.</li></ul>	<ul style="list-style-type: none"><li>• The symptoms disappeared after just three treatments.</li><li>• The daily use of blue light in particular led to the effects disappearing in just a few days.</li></ul>
<b>Lymphatic system</b> <ul style="list-style-type: none"><li>• Due to previous skin infections and lack of exercise, Lola had difficulty fighting the swelling from previous infections.</li></ul>	<ul style="list-style-type: none"><li>• Photohemotherapy and lymphatic drainage helped to reduce the swelling within a few treatments.</li></ul>
<b>Degenerative diseases</b> <ul style="list-style-type: none"><li>• Lola has only a few degenerative problems for her age but had problems walking due to an accident in September 2023. The cause was incorrectly diagnosed as hip osteoarthritis.</li></ul>	<ul style="list-style-type: none"><li>• After a WellVu screening, the source of the inflammation in the knee joints was clearly visible. After several laser treatments, the symptoms improved within a few days and the inflammation decreased significantly.</li><li>• Another WellVu screening showed the success of the adapted treatment.</li></ul>

## Conclusion of laser treatments for Lola

- In general, the laser treatments quickly showed positive effects on the treated symptoms.
- In particular, the ability to treat regularly at home whenever appropriate not only supported rapid healing, but also the fight against the microbial infections.
- In the case of microbial infections, continuous daily treatment is essential to stop microbial activity.
- Inflammation is visible under the blue light, it looks slightly red.
- Physical and mental performance increased significantly. The dog not only enjoys exercise much more and sleeps better again.
- Immunosuppressive medication and antibiotics were not necessary