



# Photobiomodulation therapy (PBMT) on acute pain and inflammation in patients who underwent total hip arthroplasty—a randomized, triple-blind, placebo-controlled clinical trial

Luciana Gonçalves Langella<sup>1,2</sup> · Heliadora Leão Casalechi<sup>1</sup> · Shaiane Silva Tomazoni<sup>3</sup> · Douglas Scott Johnson<sup>4</sup> · Regiane Albertini<sup>5</sup> · Rodney Capp Pallotta<sup>6</sup> · Rodrigo Labat Marcos<sup>6</sup> · Paulo de Tarso Camillo de Carvalho<sup>2,6</sup> · Ernesto Cesar Pinto Leal-Junior<sup>1,2</sup>

Received: 4 February 2018 / Accepted: 6 June 2018 / Published online: 16 June 2018  
© Springer-Verlag London Ltd., part of Springer Nature 2018

## Abstract

When conservative treatments fail, hip osteoarthritis (OA), a chronic degenerative disease characterized by cartilage wear, progressive joint deformity, and loss of function, can result in the need for a total hip arthroplasty (THA). Surgical procedures induced tissue trauma and incite an immune response. Photobiomodulation therapy (PBMT) using low-level laser therapy (LLLT) and/or light-emitting diode therapy (LEDT) has proven effective in tissue repair by modulating the inflammatory process and promoting pain relief. Therefore, the aim of this study was to analyze the immediate effect of PBMT on inflammation and pain of patients undergoing total hip arthroplasty. The study consisted of 18 post-surgical hip arthroplasty patients divided into two groups ( $n = 9$  each) placebo and active PBMT who received one of the treatments in a period from 8 to 12 h following THA surgery. PBMT (active or placebo) was applied using a device consisting of nine diodes (one super-pulsed laser of 905 nm, four infrared LEDs of 875 nm, and four red LEDs 640 nm, 40.3 J per point) applied to 5 points along the incision. Visual analog scale (VAS) and blood samples for analysis of the levels of the cytokines TNF- $\alpha$ , IL-6, and IL-8 were recorded before and after PBMT application. The values for the visual analog scale as well as those in the analysis of TNF- $\alpha$  and IL-8 serum levels decreased in the active PBMT group compared to placebo-control group ( $p < 0.05$ ). No decrease was observed for IL-6 levels. We conclude that PBMT is effective in decreasing pain intensity and post-surgery inflammation in patients receiving total hip arthroplasty.

**Keywords** Phototherapy · Low-level laser therapy · Light-emitting diodes · Total hip arthroplasty (THA)

## Introduction

Osteoarthritis (OA) is a degenerative joint disease characterized by the wear of articular cartilage, marginal osteophyte formation, ligament, synovial and meniscal changes, and damages of the subchondral bone [1, 2]. During early stages of the disease, the degenerative process is slow but progresses over time. In advanced stages of OA, abnormal remodeling of cartilage and formation of osteophytes irreversibly destroy the affected joint [3]. Activities of daily living (ADLs) involving load bearing at the hip joint become compromised due to pain, and prognosis is often poor [4] directly interfering with quality of life of patients [1–4].

Conservative treatment is often no longer effective in later stage of OA, and total hip arthroplasty (THA) is an alternative often used in these cases [5] to relieve symptoms [6, 7].

✉ Ernesto Cesar Pinto Leal-Junior  
ernesto.leal.junior@gmail.com

<sup>1</sup> Laboratory of Phototherapy in Sports and Exercise, Universidade Nove de Julho (UNINOVE), Rua Vergueiro 235, São Paulo, SP 01504-001, Brazil

<sup>2</sup> Postgraduate Program in Rehabilitation Sciences, Universidade Nove de Julho (UNINOVE), São Paulo, SP, Brazil

<sup>3</sup> Masters and Doctoral Programs in Physical Therapy, Universidade Cidade de São Paulo, São Paulo, SP, Brazil

<sup>4</sup> Multi Radiance Medical, Solon, OH, USA

<sup>5</sup> Federal University of São Paulo (UNIFESP), São José dos Campos, SP, Brazil

<sup>6</sup> Postgraduate Program in Biophotonics Applied to Health Sciences, Universidade Nove de Julho (UNINOVE), São Paulo, SP, Brazil

Although known as a surgical extreme procedure, post-surgical quality of life (QoL) improves and many patients often return to work [6, 7]. Even knowing that THA surgery can be successful, there are issues that need to be addressed related to postoperative pain management. Inadequate postoperative pain management is a worldwide problem, and the need to improve its management is well documented [5]. However, the tissue trauma leads to an inflammatory reaction and immune response with release of some mediators such as cytokines [8–11]; therefore, the surgical procedure can cause significant postoperative pain [12]. Postoperative pain is associated with increased hospital length of stay, delayed ambulation, and long-term functional impairment [13]. A more focused effort is needed to develop postoperative pain management, particularly during the first few days after surgery [14].

Postoperative pain management following THA is a major concern for both patients and their caregivers particularly during the first few days after surgery [14]. The rise of inflammation dominates the initial phase of repair and a postoperative pain management will likely include the use of NSAIDs for analgesia. Published studies show that most NSAIDs have an adverse effect on osteoblast growth by cell cycle arrest and apoptosis induction [15]. Also, the potential risk of heart attacks and strokes has been known for years, and it applies to even short-term use of the medication for people with or without heart disease [16].

Photobiomodulation therapy (PBMt), using low-level laser therapy (LLLT) and light-emitting diode therapy (LEDT), has been shown to be an effective in pain reduction, modulation of inflammation, and promoting repair of tissue [3, 17–20]. Additional studies have demonstrated positive effects of PBMt in cell proliferation, microcirculation, vascular neof ormation, collagen production from fibroblasts, and bone repair [21–23]. PBMt is virtually without side effects and has minimal contraindications for use. Comparisons with non-steroidal anti-inflammatory drugs (NSAIDs) in animal studies found optimal doses of PBMt and NSAIDs to be equally effective in treatment of different musculoskeletal disorders [24–35]. PBMt offers a better risk-benefit profile compared to NSAIDs and is a safe, non-pharmacological adjunct therapy in the management of acute pain.

However, there is a lack of information regarding the use of non-pharmacological complementary therapies that offer less risk of side effects, since the use of non-steroidal anti-inflammatory drugs (NSAIDs) are commonly associated with these effects [36, 37]. In addition, although NSAIDs are widely prescribed, they have been shown to have limited efficacy in pain relief [36, 37]. In this perspective, the aim of this study was to evaluate the effect of PBMt that combines multiple light sources, power outputs, and wavelengths on acute pain and serum levels of inflammatory markers in patients following postoperative hip arthroplasty.

## Material and methods

### Study design and ethics statement

A randomized, triple-blinded (patients, therapists, and outcome assessors), placebo-controlled trial was performed. The present study was submitted and approved by the research ethics committee (process number 066490). All patients voluntarily agreed to participate and signed the informed consent statement. The study was conducted at, between July and August of 2015.

### Characterization of sample

The sample size calculation was performed based on a pilot study performed by our research group. For sample size calculation, we considered the  $\beta$  value of 20% and  $\alpha$  of 5%. In pilot study used as reference for sample size calculation, it was observed that PBMt led to decreased pain (our primary outcome) using visual analog scale (VAS) to 53.90 mm ( $\pm 11.50$ ) immediately after PBMt irradiation compared to baseline ( $68.80 \pm 13.30$ ). Thus, the calculation resulted in a sample of 9 volunteers per group, 18 volunteers in total.

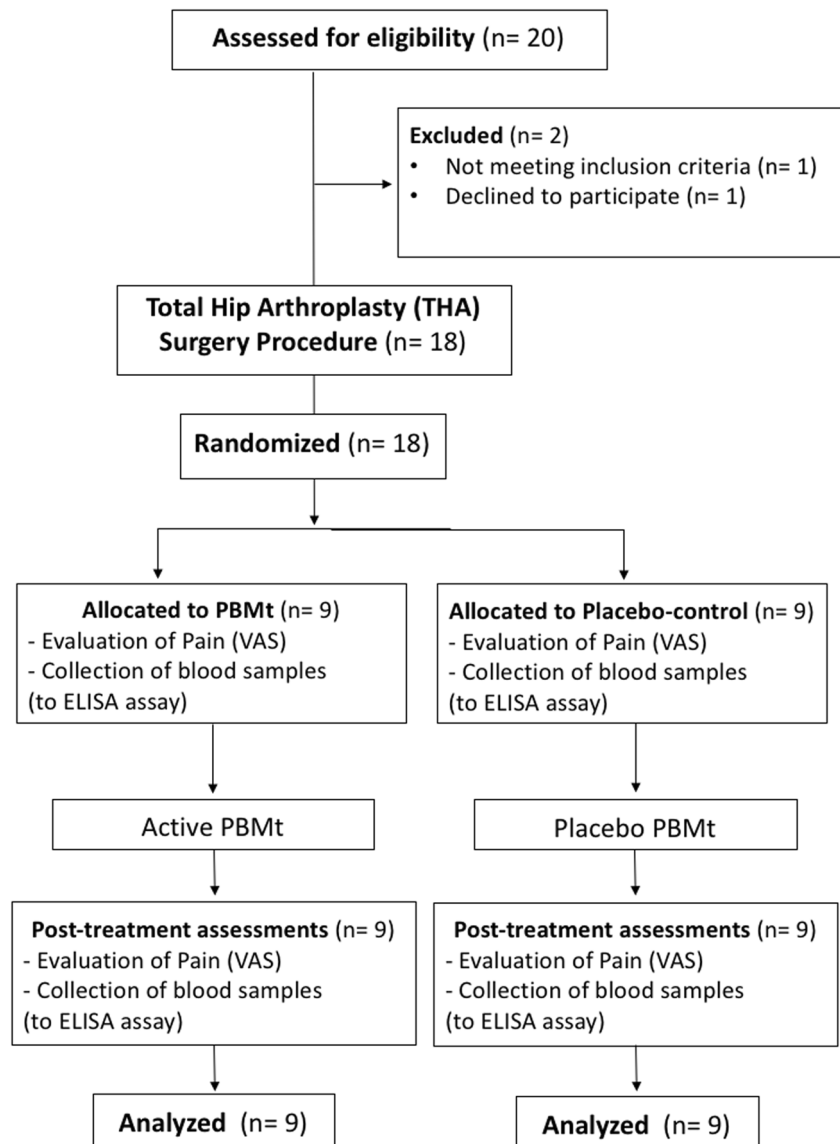
Eighteen post-surgical THA patients participated in the study. Each patient underwent the same surgical procedure and technique performed by the same surgeon. During surgery, the head and part of the neck of the femur were resected; the acetabulum was prepared to receive high-density polyethylene that fits into a metal hemi-sphere to replace the femoral head which was then connected to a rod inserted in the medullary canal of the femur. The fixing of the femoral head may or may not be cemented. The surgeon used an acrylic plastic polymethylmethacrylate, and the rod was fixed under pressure [38]. The consolidated standard of reporting trials (CONSORT) flowchart summarizing experimental procedures and subjects are shown in Fig. 1.

### Inclusion criteria and exclusion criteria

#### *Inclusion criteria:*

- Patients that were in immediate postoperative period from 8 to 12 h after total hip arthroplasty, due to diagnosis of OA. The diagnosis of OA was conducted by an orthopedic surgeon, based on the previous history of OA in these patients. In addition, the surgeon evaluated radiological images in the anteroposterior profile of the hip of these patients. The surgeon used Dejour's classification [39] to describe the severity of hip OA;
- Both genders.

Fig. 1 CONSORT flowchart



#### Exclusion criteria:

- Any hip surgery that was not due to OA;
- Any hip surgery other than total arthroplasty;
- Neurological and cognitive problems, as dementia, mental retardation, communicative deficit, or any other condition that would make it impossible to understand the study procedures;
- Postoperative complications such as deep vein thrombosis and infections.

#### Randomization

Prior to initiation of treatment, the 18 patients were randomized into two experimental groups (nine patients per group). Randomization was carried out by a simple drawing of lots (A

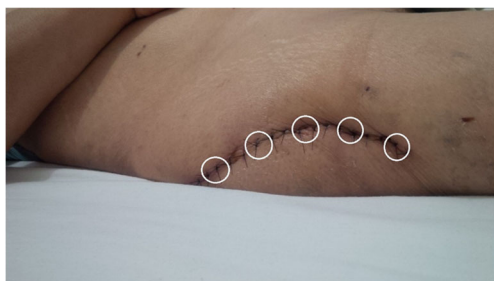or B) performed by a participating researcher not involved with the recruitment or evaluation of patients. This same researcher was responsible for programming the PBMt device according to the result of the randomization and was instructed to not disclose the identity of the devices to anyone involved in the study. The PBMt device used displayed the same setting and emitted the same sounds regardless of the programmed dose and mode (active PBMt or placebo PBMt). Patient and therapist were blinded throughout the treatment. Randomization labels were created using a randomization table at a central office. Concealed allocation was achieved through the use of sequentially numbered, sealed, and opaque envelopes.

#### Interventions

A single application of PBMt (active or placebo) was performed within postoperative period from 8 to 12 h, immediately

after the baseline evaluation. The active and placebo PBMt were performed using the same device and the irradiated sites were the same in both therapies. To ensure blinding for patients and therapists, the device emitted the same sounds and the same information on the display regardless of the programmed mode (active or placebo). The device in the placebo mode and in the active mode had the brightness of the red light source, but in the placebo mode, the emitted light had only 0.5 mW of power output for each red diode, and both super-pulsed laser, infrared LEDs, and magnetic field were turned off. This amount of power used in placebo mode is negligible but ensures the brightness of the red light without therapeutic effects. In this way, it is impossible to discern between the two PBMt modes (placebo and active). The device was previously coded as active or placebo modes, and only one researcher not involved in the randomization, treatment, and evaluation was aware of these codes. The intervention specifications were as follows:

1. *PBMt group*: PBMt was applied using a cordless, portable PainAway/PainCure™ device (manufactured by Multi Radiance Medical, Solon-OH, USA) at five sites/points over the full extent of the surgical scar, with a distance of 2 cm between sites (Fig. 2). The cluster style emitter contains 9 diodes comprising 1 super-pulsed laser diode (905 nm, 2.7 mW average power, 8.5 W peak power, and 0.81 J dose for each diode), 4 red LEDs (640 nm, 15 mW average power, and 4.5 J dose for each diode), and 4 infrared LEDs (875 nm, 17.5 mW average power, and 5.25 J dose for each diode). The total irradiation time per site was 300 s and the total energy delivered was 39.8 J. The choice of these parameters was based on a previous study using the same technology [40]. The optical power of the device was checked before irradiation (in each patient) by a researcher that was not involved in data collection and analysis. For such, it was employed a Thorlabs® thermal power meter (Model S322C, Thorlabs®, Newton-NJ, USA). The full description of PBMt parameters is provided in Table 1.
2. *Placebo-control group*: The placebo PBMt was delivered using the same device that active PBMt but without any emission of therapeutic dose (placebo mode). Patients



**Fig. 2** Sites of PBMt and placebo irradiation (white circles) on the surgical scar

received a total negligible dose of 0.6 J per point/site in placebo mode. Furthermore, the sources of infrared light and superpulsed are off and the electromagnetic field is inactive.

## Outcomes

The outcomes were pain intensity and levels of cytokines (interleukin [IL]-6, IL-8, and tumor necrosis factor alpha [TNF- $\alpha$ ]) obtained at baseline (pre-treatment) and immediately (within 10 min) after irradiation with PBMt (post-treatment). These outcomes were collected by an assessor who was not aware of patient allocation to their treatment groups.

The primary outcome of the study was pain intensity measured by visual analog scale (VAS). Visual analog scale (VAS) evaluates pain intensity levels perceived by the patient, with assistance of an assessor, on a scale ranging from 0 to 100 mm, with 0 being “no pain” and 100 being “the worst possible pain”.

The secondary outcome of the study was the cytokine levels measured by *enzyme-linked immunosorbent assay (ELISA) method*. For such, blood samples were collected by a qualified nurse blinded to group allocation and were obtained from the antecubital vein. One hour after collection, each sample was centrifuged at 3000 rpm for 20 min. Pipettes were used to transfer the serum to Eppendorf® tubes, which were stored at  $-80^{\circ}\text{C}$  until analysis. The levels of IL-6, IL-8, and TNF- $\alpha$  in the blood samples were determined by enzyme-linked immunosorbent assays, using a commercial kit and following the manufacturer’s instructions (BD Biosciences®, USA). Spectrophotometric readings were performed in a SpectraMax® Plus 384 Absorbance Plate Reader (Sunnyvale, CA, USA) with 450-nm wavelength and correction to 570 nm. The results were expressed in pg/ml.

## Statistical analysis

The statistical analysis was conducted following the principles of intention-to-treat analysis [41]. Initially, the data was tabulated and evaluated for normality using the Shapiro-Wilk test. As a normal distribution was verified, unpaired, two-tailed, Student’s *t* test was used to detect difference among groups. The significance level was set at  $p < 0.05$ . The data in the graphs are presented as mean and standard error of the mean ( $\pm$ SEM). The researcher that completed the statistical analysis was blinded to randomization and allocation of patients in experimental groups.

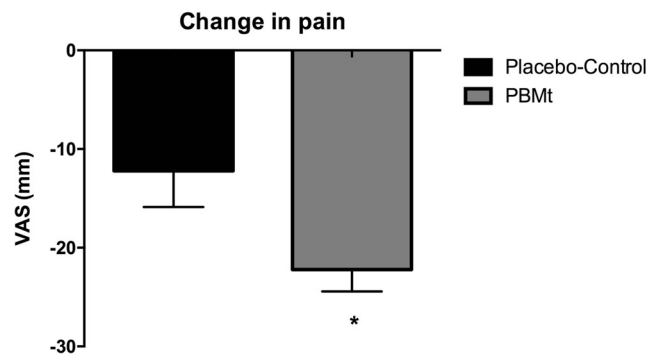
**Table 1** Parameters for PBMt

Number of lasers	One super-pulsed infrared
Wavelength (nm)	905 ( $\pm 1$ )
Frequency (Hz)	3000
Peak power (W)	8.5
Average optical output (mW)	2.7
Power density (mW/cm <sup>2</sup> )	9.66
Energy density (J/cm <sup>2</sup> )	2.9
Dose (J)	0.81
Spot size of laser (cm <sup>2</sup> )	0.4
Number of red LEDs	4 Red
Wavelength of red LEDs (nm)	640 ( $\pm 10$ )
Frequency (Hz)	2
Average optical output (mW)—each	15
Power density (mW/cm <sup>2</sup> )—each	16.66
Energy density (J/cm <sup>2</sup> )—each	5
Dose (J)—each	4.5
Spot size of red LED (cm <sup>2</sup> )—each	0.9
Number of infrared LEDs	4 Infrared
Wavelength of infrared LEDs (nm)	875 ( $\pm 10$ )
Frequency (Hz)	16
Average optical output (mW)—each	17.5
Power density (mW/cm <sup>2</sup> )—each	19.44
Energy density (J/cm <sup>2</sup> )—each	5.83
Dose (J)—each	5.25
Spot size of LED (cm <sup>2</sup> )—each	0.9
Magnetic field (mT)	35
Irradiation time per site (s)	300
Total energy delivered (J)	39.8
Aperture of device (cm <sup>2</sup> )	4
Application mode	Cluster probe held stationary with slight contact with patient skin with a 90-degree angle.

## Results

Eighteen acute postoperative arthroplasty patients were recruited for this study and completed all procedures with no dropouts. The average age in PBMt group was 69 ( $\pm 5.6$ ), height of 165.00 cm ( $\pm 11.00$ ), and body weight of 70 ( $\pm 9.56$ ), 55.5% were male and 44.4% female. In the placebo-control group, average age was 67 ( $\pm 6.4$ ), height of 169.00 cm ( $\pm 5.00$ ), and body weight of 79 kg ( $\pm 11.00$ ), 33.3% were male and 66.6% female. There was no difference between experimental groups for demographics' characteristics ( $p > 0.05$ ).

Figure 3 demonstrates that PBMt significantly decreased ( $p < 0.05$ ) pain compared to placebo-control. At baseline (before treatment), placebo-control group showed 56.70 mm ( $\pm 10.00$ ) at VAS scale, while PBMt group showed 65.60 ( $\pm$



**Fig. 3** Change in pain assessed using 100 mm VAS. Values are mean and error bars are SEM. Asterisk indicates significant difference between placebo/control and PBMt groups ( $p < 0.05$ )

12.40), without difference between groups. Immediately following treatment, PBMt group decreases pain intensity when compared to placebo-control group ( $p < 0.05$ ), as shown in Fig. 3.

As shown in Fig. 4, the levels of IL-6 showed no statistically significant difference between the placebo-control (pre-treatment 361.67  $\pm$  29.89 pg/ml and post-treatment 352.88  $\pm$  18.32 pg/ml) and PBMt groups (pre-treatment 350.30  $\pm$  33.38 pg/ml and post-treatment 338.19  $\pm$  28.60 pg/ml) at none time points tested.

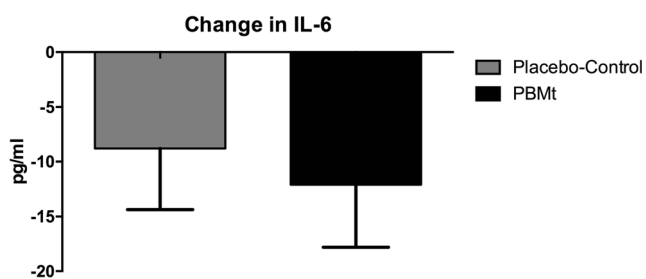
The levels of IL-8 in placebo-control and PBMt groups were 191.29 pg/ml ( $\pm 15.52$ ) and 190.28 pg/ml ( $\pm 15.99$ ), respectively, showing homogeneity between groups at baseline evaluation. At post-treatment evaluation, there was a statistically significant decrease in IL-8 in favor of PBMt group compared to placebo-control group ( $p < 0.05$ ), as showed in Fig. 5.

The levels of TNF- $\alpha$  in placebo-control and PBMt groups were 467.73 pg/ml ( $\pm 24.47$ ) and 469.88 pg/ml ( $\pm 26.50$ ), respectively, showing again homogeneity between groups at baseline evaluation. At post-treatment evaluation, there was a statistically significant decrease in TNF- $\alpha$  in favor of PBMt group compared to placebo-control group ( $p < 0.05$ ), as shown in Fig. 6.

## Discussion

The results of this study support the hypothesis that photobiomodulation therapy applied to the surgical incision in the postoperative period reduces acute pain and inflammation in patients after hip arthroplasty. Previous studies using laser therapy and the visual analog scale as a means of evaluation also reported less pain in the post-surgical period, corroborating the results of this study [42–44].

Photobiomodulation therapy has been identified as an effective, safe, and non-invasive modality able to modulate the inflammatory process [17, 18, 20, 36]. The current study adds to this collective body of evidence. It is



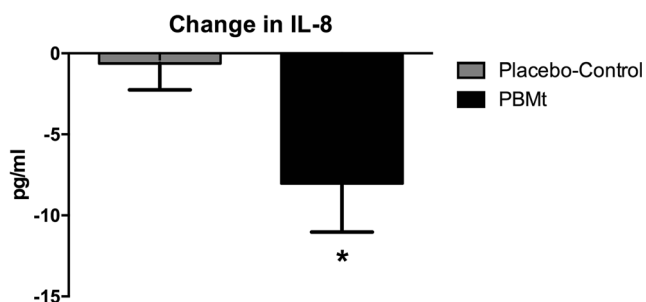
**Fig. 4** Change in IL-6 levels measured by ELISA immunoenzymatic assay. Values are mean and error bars are SEM

known that surgical injuries in the hip joint induce immune response mediated by inflammatory cytokines [8–11].

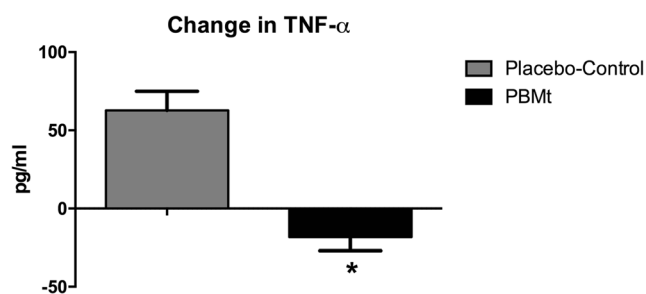
There was modulation of the inflammatory process in the arthroplasty postoperative period in the group treated with the active phototherapy. These results are in accordance with previous studies in the literature in which authors demonstrated decreased in pain scores and inflammatory markers in patients treated with laser therapy over the surgical incision in tibial fractures postoperative [45]. Decrease in pain and reduced administration of analgesic drugs was also observed in patients treated with laser therapy in distal radius fracture in the immediate postoperative period [46].

In order to observe the action of PBMt on serum levels of proinflammatory cytokines IL-6, IL-8, and TNF- $\alpha$ , mediators released during acute inflammation, we performed an analysis using the immunoenzymatic test. In this study, we chose not to perform blood tests before the surgery, since there is a prior consensus in the scientific literature regarding the increase of cytokines and their kinetic behavior, which occur after post-surgical hip arthroplasty, highlighting the acute inflammatory character [9, 11, 47].

Our results show reduced IL-6 levels in the group treated with effective PBMt, although this reduction was not statistically significant. The results are consistent with previous studies that investigated the effects of PBMt in decreased IL-6 release [17, 21]. This reduction in IL-6 release may not



**Fig. 5** Change in IL-8 levels measured by ELISA immunoenzymatic assay. Values are mean and error bars are SEM. Asterisk indicates significant difference between placebo-control and PBMt groups ( $p < 0.05$ )



**Fig. 6** Change in TNF- $\alpha$  levels measured by ELISA immunoenzymatic assay. Values are mean and error bars are SEM. Asterisk indicates significant difference between placebo-control and PBMt groups ( $p < 0.05$ )

be significant because of the short time interval chosen between the end of surgery and the application (8 to 12 h after surgery). Several authors report that an increase in peak concentrations occurs on the first day and remains until the third day post-surgery [10, 11].

Regarding the release of IL-8, our results show a statistically significant decrease in serum levels of this cytokine in the group treated with effective PBMt. This allows us to infer that PBMt attenuates the levels of this cytokine. A previous study showed increased IL-8 at the end of surgery with peaks in 6 h and decrease on the first day, indicating its chemotactic character and short duration [11]. The findings of this study also indicate a statistically significant decrease in serum levels of proinflammatory cytokine TNF- $\alpha$ . Since in the early stages of inflammation, an increased presence of TNF- $\alpha$  stimulates IL-6 and IL-8 synthesis attributing the acute inflammatory process in surgical trauma [8, 10, 11], modulation of this cytokine minimizes this process. Thus, once the action of these mediators is controlled, the patient has a less aggressive inflammatory process due to the surgical procedure [11]. Acute inflammation can lead to functional impairment to the patient. Therefore, modulation, not elimination, of the inflammatory process and its subsequent signs and symptoms is paramount to the success of the tissue repair and quality.

Our results provide us with evidence that a single application of PBMt added to postoperative treatment attenuates inflammation and significantly reduces acute inflammatory pain. These results point to a possible decrease in the administration of analgesic drugs, which besides having high cost for health systems and have adverse or side effects [36, 37]. Improving pain control may decrease length of stay, decrease costs, enhance functional recovery, and improve long-term functional outcomes [13].

The results also provide a better understanding of the role of PBMt with the parameters used on the modulation of inflammatory mediators, as well as in the decrease of pain, being of great value, since it may guide future therapeutic interventions. However, it is important to highlight that the parameters

used in the present study were chosen according to previous study [40] and according to instructions provided by the manufacturer. Further studies are important to substantiate the findings described in this study and to investigate if the parameters used are the most adequate for pain control in patients submitted to THA.

This study has some limitations such as the lack of assessment of cytokines prior to surgery in order to have more data to ensure the homogeneity of groups, which happened due to our full access to patients only after the surgery, making impossible to analyze the inflammatory markers before the surgery. However, it is important to highlight that the analysis of these mediators after the surgery (before treatments) showed homogeneity between the groups. Finally, it is important to report that magnetic therapy may have an effect of reducing pain, and this aspect warrants further investigation.

## Conclusion

In this study, PBMt (phototherapy) with the parameters used as the immediate postoperative treatment of hip arthroplasty provided pain decrease and decreased serum levels of proinflammatory cytokines (IL-6, IL-8, and TNF- $\alpha$ ). PBMt is a safe treatment and without reported side effects, and can be suggested as a possible therapeutic modality in the immediate hip arthroplasty postoperative period.

**Funding** This study was supported by research grants 2010/52404-0 from São Paulo Research Foundation-FAPESP (Professor Ernesto Cesar Pinto Leal-Junior), 310281/2017-2 from Brazilian Council of Science and Technology Development-CNPq (Professor Ernesto Cesar Pinto Leal-Junior). FAPESP and CNPq had no role in the planning of this study; they had no influence on study design, data collection and analysis, decision to publish, or preparation of the article.

## Compliance with ethical standards

The present study was submitted and approved by the research ethics committee (process number 066490). All patients voluntarily agreed to participate and signed the informed consent statement.

**Competing interests** Professor Ernesto Cesar Pinto Leal-Junior receives research support from Multi Radiance Medical (Solon, OH, USA), a phototherapy/photobiomodulation device manufacturer. Douglas Scott Johnson is an employee and a shareholder of Multi Radiance Medical (Solon-OH, USA). The remaining authors declare that they have no conflict of interests.

**Ethical aspects** All experimental procedures were submitted and approved by the Research Ethics Committee of Nove de Julho University (process number 066490). All patients signed an informed consent form prior to enrollment.

## References

1. Brandt KD, Dieppe P, Radin E (2009) Etiopathogenesis of osteoarthritis. *Med Clin North Am* 93:1–24
2. Bondeson J, Blom AB, Wainwright S, Hughes C, Caterson B, Van den Berg WB (2010) The role of synovial macrophages and macrophage-produced mediators in driving inflammatory and destructive responses in osteoarthritis. *Arthritis Rheum* 62:647–657
3. Da Rosa AS, dos Santos AF, da Silva MM, Facco GG, Perreira DM, Alves AC, Leal Junior EC, de Carvalho Pde T (2012) Effects of low-level laser therapy at Wavelengths of 660 and 808 nm in experimental model of osteoarthritis. *Photochem Photobiol* 88:161–166
4. Corti CM, Rigon C (2003) Epidemiology of osteoarthritis: prevalence risk factors and functional impact. *Aging Clin Exp Res* 15: 359–363
5. Taylor A, Stanbury L (2009) A review of postoperative pain management and the challenges. *Curr Anaesth Crit Care* 20:188–194
6. Zavadak KH, Gibson KR, Wititley DM, Britz P, Kwok CK (1995) Variability in the attainment of functional milestones during the care admission after total joint replacement. *J Rheumatol* 22:482–487
7. Hawker GA, Wright JG, Coyte PC, Williams JI, Harvey B, Glazier R (2001) Determining the need for hip and knee arthroplasty: the role of clinical severity and patients preferences. *Med Care* 39:206–216
8. Beloosesky Y, Hendel D, Weiss A, Heishkovitz A, Grinblat J, Pirotsky A, Barak V (2007) Cytokines and C-reactive protein production in hip-fracture-operated elderly patients. *J Gerontol A Biol Sci Med Sci* 62:420–426
9. Shah K, Mohammed A, Patil S, McFadyen A, Meek RMD (2009) Circulating cytokines after hip and knee arthroplasty: a preliminary study. *Clin Orthop Relat Res* 467:946–951
10. Kwak S, Chun Y, Rhyu K, Cha J, Cho Y (2014) Quantitative analysis of tissue injury after minimally invasive Total hip arthroplasty. *Clin Orthop Surg* 6:279–284
11. Reikeras O, Borgen P, Reselandand JE, Lyngstadaas SP (2014) Changes in serum cytokines in response to musculoskeletal surgical trauma. *BMC Res Notes* 7:128–132
12. Ferreira CHJF, Beleza ACS (2007) Abordagem fisioterapêutica da dor pós-operatória. *Rev Col Bras Surg* 34:127–130
13. Morrison RS, Magaziner J, McLaughlin MA, Orosz G, Silberzweig SB, Koval KJ, Siu AL (2003) The impact of post-operative pain on outcomes following hip fracture. *Pain* 103:303–311
14. Joelsson M, Olsson LE, Jakobsson E (2010) Patients' experience of pain and pain relief following hip replacement surgery. *J Clin Nurs* 19:2832–2838
15. Giannoudis PV, Hak D, Sanders D, Donohoe E, Tosounidis T, Bahney C (2015) Inflammation, bone healing, and anti-inflammatory drugs: an update. *J Orthop Trauma* 29:S6–S9
16. Jin J (2015) JAMA PATIENT PAGE. Nonsteroidal anti-inflammatory drugs. *JAMA* 314:1084
17. Alves ACA, Vieira RP, Leal Junior EC, dos Santos AS, Ligeiro AP, Albertini R, Silva Junior JA, de Carvalho PTC (2013) Effect of low-level laser therapy on the expression of inflammatory mediators and on neutrophils and macrophages in acute joint inflammation. *Arthritis Res Ther* 15:R116
18. Pallotta RC, Bjordal JM, Frigo L, Leal Junior EC, Teixeira S, Marcos RL, Ramos L, Messias Fde M, Lopes-Martins RA (2011) Infrared (810-nm) low-level laser therapy on rat experimental knee inflammation. *Lasers Med Sci* 27:71–78
19. Herpich CM, Leal-Junior ECP, Gomes CAFP, Gloria IPDS, Amaral AP, Amaral MFRS, Politti F, Biasotto-Gonzalez DA (2017) Immediate and short-term effects of phototherapy on pain, muscle activity, and joint mobility in women with temporomandibular disorder: a randomized, double-blind, placebo-controlled, clinical trial. *Disabil Rehabil*

20. Helrigle C, Pd DC, Casalechi HL, Leal-Junior EC, Fernandes GH, Helrigel PA, Rabelo RL, De Oliveira Aleixo-Junior I, Aimbire F, Albertini R (2016) Effects of low-intensity non-coherent light therapy on the inflammatory process in the calcaneal tendon of ovariectomized rats. *Lasers Med Sci* 31:33–40
21. Dos Santos SA, Alves ACA, Leal Junior EC, Albertini R, Vieira RP, Ligeiro AP, Silva Junior JA, de Carvalho PTC (2014) Comparative analysis of two low-level laser doses on the expression of inflammatory mediators and on neutrophils and macrophages in acute joint inflammation. *Lasers Med Sci* 29:1051–1058
22. Casalechi HL, de Farias Marques AC, da Silva EAP, Aimbire F, Marcos RL, Lopes-Martins RAB, de Carvalho Pde T, Albertini R (2014) Analysis of the effect of phototherapy in model with traumatic Achilles tendon injury in rats. *Lasers Med Sci* 12:1075–1081
23. Carvalho Pde T, Silva IS, Reis FA, Belchior AC, Facco GG, Guimarães RN, Fernandes GH, Denadai AS (2006) Effect of 650 nm low-power laser on bone morphogenetic protein in bone defects induced in rat femors. *Acta Cir Bras* 21:63–68
24. De Almeida P, Lopes-Martins RÁ, Tomazoni SS, Albuquerque-Pontes GM, Santos LA, Vanin AA, Frigo L, Vieira RP, Albertini R, de Carvalho Pde T, Leal-Junior EC (2013) Low-level laser therapy and sodium diclofenac in acute inflammatory response induced by skeletal muscle trauma: effects in muscle morphology and mRNA gene expression of inflammatory markers. *Photochem Photobiol* 89:501–507
25. De Almeida P, Tomazoni SS, Frigo L, de Carvalho Pde T, Vanin AA, Santos LA, Albuquerque-Pontes GM, De Marchi T, Tairova O, Marcos RL, Lopes-Martins RÁ, Leal-Junior EC (2014) What is the best treatment to decrease pro-inflammatory cytokine release in acute skeletal muscle injury induced by trauma in rats: low-level laser therapy, diclofenac, or cryotherapy? *Lasers Med Sci* 29:653–658
26. Tomazoni SS, Frigo L, Dos Reis Ferreira TC, Casalechi HL, Teixeira S, de Almeida P, Muscara MN, Marcos RL, Serra AJ, de Carvalho PTC, Leal-Junior ECP (2017) Effects of photobiomodulation therapy and topical non-steroidal anti-inflammatory drug on skeletal muscle injury induced by contusion in rats-part 1: morphological and functional aspects. *Lasers Med Sci* 32:2111–2120
27. Tomazoni SS, Frigo L, Dos Reis Ferreira TC, Casalechi HL, Teixeira S, de Almeida P, Muscara MN, Marcos RL, Serra AJ, de Carvalho PTC, Leal-Junior ECP (2017) Effects of photobiomodulation therapy and topical non-steroidal anti-inflammatory drug on skeletal muscle injury induced by contusion in rats-part 2: biochemical aspects. *Lasers Med Sci* 32:1879–1887
28. Ramos L, Leal Junior EC, Pallotta RC, Frigo L, Marcos RL, de Carvalho MH, Bjordal JM, Lopes-Martins RÁ (2012) Infrared (810 nm) low-level laser therapy in experimental model of strain-induced skeletal muscle injury in rats: effects on functional outcomes. *Photochem Photobiol* 88:154–160
29. Tomazoni SS, Leal-Junior EC, Frigo L, Pallotta RC, Teixeira S, de Almeida P, Bjordal JM, Lopes-Martins RÁ (2016) Isolated and combined effects of photobiomodulation therapy, topical nonsteroidal anti-inflammatory drugs, and physical activity in the treatment of osteoarthritis induced by papain. *J Biomed Opt* 21:108001
30. Tomazoni SS, Leal-Junior EC, Pallotta RC, Teixeira S, de Almeida P, Lopes-Martins RÁ (2017) Effects of photobiomodulation therapy, pharmacological therapy, and physical exercise as single and/or combined treatment on the inflammatory response induced by experimental osteoarthritis. *Lasers Med Sci* 32:101–108
31. Da Rosa AS, dos Santos AF, da Silva MM, Facco GG, Perreira DM, Alves AC, Leal Junior EC, de Carvalho Pde T (2012) Effects of low-level laser therapy at wavelengths of 660 and 808 nm in experimental model of osteoarthritis. *Photochem Photobiol* 88:161–166
32. Dos Santos SA, Alves AC, Leal-Junior EC, Albertini R, Vieira RP, Ligeiro AP, Junior JA, de Carvalho Pde T (2014) Comparative analysis of two low-level laser doses on the expression of inflammatory mediators and on neutrophils and macrophages in acute joint inflammation. *Lasers Med Sci* 29:1051–1058
33. Marcos RL, Leal Junior EC, Messias Fde M, de Carvalho MH, Pallotta RC, Frigo L, dos Santos RA, Ramos L, Teixeira S, Bjordal JM, Lopes-Martins RÁ (2011) Infrared (810 nm) low-level laser therapy in rat achilles tendinitis: a consistente alternative to drugs. *Photochem Photobiol* 87:1447–1452
34. Marcos RL, Leal-Junior EC, Arnold G, Magnenet V, Rahouadj R, Wang X, Demeurie F, Magdalou J, de Carvalho MH, Lopes-Martins RÁ (2012) Low-level laser therapy in collagenase-induced Achilles tendinitis in rats: analyses of biochemical and biomechanical aspects. *J Orthop Res* 30:1945–1951
35. Laraia EM, Silva IS, Pereira DM, dos Reis FA, Albertini R, de Almeida P, Leal Junior EC, de Tarso Camillo de Carvalho P (2012) Effect of low-level laser therapy (660 nm) on acute inflammation induced by tenotomy of Achilles tendon in rats. *Photochem Photobiol* 88:1546–1550
36. Bjordal JM, Ljunggren AE, Klovning A, Slørdal L (2004) Non-steroidal anti-inflammatory drugs, including cyclo-oxygenase-2 inhibitors, in osteoarthritic knee pain: meta-analysis of randomised placebo-controlled trials. *Br Med J* 329:1317
37. Bjordal J, Klovning A, Ljunggren A, Slørdal L (2007) Short-term efficacy of pharmacotherapeutic interventions in osteoarthritic knee pain: a meta-analysis of randomized placebo-controlled trials. *Eur J Pain* 11:125–138
38. Harris WH, Sledge CB (1990) Total hip and total knee replacement (first of two parts). *N Engl J Med* 323:725–731
39. Dejour H, Carret JP, Walch G (1991) Les Gonarthroses. In: 7èmes Journées Lyonnaises de Chirurgie de Genou. Lyon
40. Leal-Junior EC, Johnson DS, Saltmarche A, Demchak T (2014) Adjunctive use of combination of super-pulsed laser and light-emitting diodes phototherapy on nonspecific knee pain: double-blinded randomized placebo-controlled trial. *Lasers Med Sci* 29:1839–1847
41. Elkins MR, Moseley AM (2015) Intention-to-treat analysis. *J Physiother* 61:165–167
42. Oliveira SS, Melo DA, Mesquita FRA, Maia AP, Bussadori SK, Santos FKP (2013) Effect of low-level laser therapy on the post-surgical inflammatory process after third molar removal: study protocol for a double-blind randomized controlled trial. *Trials* 6:373
43. Merigo M, Vescovi P, Ricotti E, Stea S, Meleti M, Manfredi M, Fornaini C (2015) Efficacy of LLLT in swelling and pain control after the extraction of lower impacted third molars. *Laser Ther* 24:39–46
44. Fabre HS, Navarro RL, Oltramari-Navarro PV, Oliveira RF, Pires-Oliveira DA, Andraus RA, Fuirini N, Fernandes KB (2015) Anti-inflammatory and analgesic effects of low-level laser therapy on the postoperative healing process. *J Phys Ther Sci* 27:1645–1648
45. Nesioonpour S, Mokmeli S, Vojdani S, Mohtadi A, Akhondzadeh R, Behaeen K, Moosavi S, Hojjati S (2014) The effect of low-level laser on postoperative pain after tibial fracture surgery: a double-blind controlled randomized clinical trial. *Anesth Pain Med* 4:e17350
46. Nesioonpour S, Mokmeli S, Akhondzadeh R, Moosavi S, Mackie M, Naderan M (2014) Does low-level laser therapy enhance the efficacy of intravenous regional anesthesia? *Pain Res Manag* 19:154–158
47. Defu YU, Zongsheng YIN, Changma FU, Runze YU (2014) Impact on red blood cell immunity patterns in postoperative phase following total hip arthroplasty. *Cent Eur J Immunol* 39:377–383