



Intraoral photobiomodulation diminishes pain and improves functioning in women with temporomandibular disorder: a randomized, sham-controlled, double-blind clinical trial

Intraoral photobiomodulation diminishes pain in women with temporomandibular disorder

Carolina Marciela Herpich^{1,2} · Ernesto Cesar Pinto Leal-Junior³ · Fabiano Politti³ · Cid André Fidelis de Paula Gomes¹ · Igor Phillip dos Santos Glória³ · Maitê de Freitas Rocha de Souza Amaral³ · Graciela Herpich³ · Ludmila Menezes Alves de Azevedo³ · Tabajara de Oliveira Gonzalez¹ · Daniela Aparecida Biasotto-Gonzalez³

Received: 30 January 2019 / Accepted: 2 July 2019
© Springer-Verlag London Ltd., part of Springer Nature 2019

Abstract

The aim of the present study was to evaluate the effect of intraoral photobiomodulation involving super-pulsed laser (905 nm) combined with red (640 nm) and infrared (875 nm) light-emitting diodes on pain, mandibular range of motion, and functioning in women with myogenous temporomandibular disorder. A randomized, sham-controlled, double-blind clinical trial was conducted involving 30 women with myogenous temporomandibular disorder diagnosed using the Research Diagnostic Criteria for Temporomandibular Disorders. The participants were randomly allocated to two groups (active and sham photobiomodulation). The evaluations involved this use of the visual analog scale, digital calipers, and a functional scale. Photobiomodulation was administered intraorally in the region of the pterygoid muscles, bilaterally, in all participants for a total of six sessions. Evaluations were performed on five occasions: prior to the intervention, immediately after the first session, 24 h and 48 h after the first session, and after the six sessions. Significant differences between groups were found regarding pain ($p \leq 0.01$) and functioning ($p \leq 0.04$). However, no statistically significant difference was found regarding range of mandibular motion. The findings demonstrate that intraoral photobiomodulation involving super-pulsed laser (905 nm) combined with red (640 nm) and infrared (875 nm) light-emitting diodes diminishes pain and improves functioning but does not exert an influence on mandibular range of motion in women with temporomandibular disorder.

Trial registration: NCT02839967

Keywords Temporomandibular joint dysfunction · Pain · Physiotherapeutic modalities · Temporomandibular disorder syndrome · Lasers · Phototherapy

Introduction

Temporomandibular joint disorders are a heterogeneous group of conditions that affect the temporomandibular joints (TMJ),

muscles of the mandible, and/or related structures [1]. Pain is one of the most common and limiting clinical manifestations of this disorder [2–5]. Moreover, women have a twofold greater chance of experiencing pain symptoms than men [6] due mainly to hormonal, biological, and psychosocial factors [7]. The complexity temporomandibular disorder (TMD) requires the involvement of a multidisciplinary team to ensure effective treatment [8].

Photobiomodulation has been used for the treatment of TMD. This physiotherapeutic modality consists of the application of low-level laser [9–12] or light-emitting diodes [13]. Manual therapies have also been employed [14]. Both modalities are always administered to extraoral structures [15]. However, based on knowledge of symptoms reported during

✉ Carolina Marciela Herpich
carolinaherpich@gmail.com

¹ Department of Physical Therapy, University Nove de Julho, São Paulo, Brazil

² Arujá, Brazil

³ Department of Postgraduate Program in Rehabilitation Sciences, University Nove de Julho, São Paulo, Brazil

palpation of the lateral pterygoid region in clinical examinations using the Research Diagnostic Criteria for Temporomandibular Disorders (RDC/TMD) [10, 16] as well as the favorable results of manual techniques applied in the lateral pterygoid region [17] and on nearby structures [18] regarding the reduction in pain, it is plausible that the intraoral administration of photobiomodulation could have beneficial effects.

This possibility is strengthened by the known involvement of the lateral pterygoid muscle in chronic degenerative diseases of the TMJ [19] as well as the emergence of a new photobiomodulation modality involving a combination of low-level laser and light-emitting diodes with different wavelengths in the same device. Studies report that the combination of multiple wavelengths offers benefits [20], such as a reduction in non-specific knee pain [21], a reduction in pain in patients with fibromyalgia [22], as well as improvements in TMD following a single application [15].

Therefore, the aim of the present study was to evaluate the effects of intraoral photobiomodulation involving super-pulsed laser (905 nm) combined with red (640 nm) and infrared (875 nm) light-emitting diodes on pain, mandibular range of motion, and functioning in women with myogenous TMD. The hypothesis was that photobiomodulation with a combination of different light sources reduces pain, increases mandibular range of motion, and exerts a positive influence on functioning in individuals with myogenous TMD.

Methods

The present randomized, sham-controlled, double-blind clinical trial received approval from the Human Research Ethics Committee of University Nove de Julho, São Paulo, Brazil (certificate number: 42264715.0.0000.5511), and the protocol was registered with clinicaltrials.gov (NCT02839967). This clinical trial was conducted with patients referred from the Department of Physical Therapy of the University Nove de Julho. All volunteers received clarifications regarding the objectives and procedures of the study and those who agreed to participate signed a statement of informed consent.

Thirty-eight patients were screened based on the eligibility criteria. The inclusion criteria were the female sex, a diagnosis of myogenous and/or mixed TMD based on the RDC/TMD, and moderate to severe pain according to the palpation of lateral pterygoid (question 10a of the RDC/TMD clinical axis) and visual analog scale (VAS) score of 3 to 8 [23]. The exclusion criteria were missing teeth, use of complete or partial dentures, systemic or neuromuscular disease, a history of trauma to the face or TMD, history of luxation of the TMJ, currently undergoing orthodontic treatment, or currently using medication that affects the musculoskeletal system (analgesics, anti-inflammatory agents, or muscle relaxants). Based

on these criteria, 30 women were selected to participate in the present study.

Procedures

This study was conducted in accordance with the Consolidated Standards of Reporting Clinical Trials (CONSORT statement) to enable greater transparency and better quality of the results.

The 30 individuals were randomized into groups according to a spread sheet generated in a computer program. Randomization occurred in the order in which each patient was enrolled in the study: Treatment group and sham group. The randomization procedure was performed by a researcher who was not involved in the recruitment, evaluation, or treatment of the participants. A physiotherapist with at least 3 years of experience in a 2-month training period for procedure administration was assigned to perform the treatments according to the outcome of the randomization. A blind examiner assessed the clinical results before, immediately, 24 and 48 h after a session, and after 6 sessions within 2 weeks of phototherapy.

The participants were informed that they would receive treatment involving phototherapy and were blinded to whether the treatment was active or placebo. The study was divided into five evaluation phases and two treatment phases.

Evaluation 1: The RDC/TMD [10] was administered to classify the type of TMD. Mandibular range of motion was determined with the aid of digital calipers. Pain intensity was assessed using the VAS. Functioning was evaluated using the Patient-Specific Functional Scale.

Treatment 1: After randomization, photobiomodulation was administered in a single session according to the respective groups (active or sham).

Evaluation 2: Immediately after treatment, mandibular range of motion was determined with the aid of digital calipers and pain intensity was assessed using the VAS.

Evaluation 3: 24 h after treatment, the protocol used in evaluation 2 was repeated.

Evaluation 4: 48 h after treatment, the protocol used in evaluations 2 and 3 was repeated.

Treatment 2: Six sessions of photobiomodulation were held at a frequency of three times a week for 2 weeks according to the respective groups (active or sham).

Evaluation 5: 24 h after the last session of photobiomodulation, the protocol used in evaluation 1 was repeated.

The visual analog scale (VAS) was used for the assessment of pain intensity, which consists of a straight line measuring 10 cm in length with the words “no pain” printed at one end

and “worst pain ever felt” printed at the other end. The participant was instructed to place a perpendicular mark on the line at the point between the two extremes the best represented her pain at that moment of rest [23]. Mandibular range of motion was measured using digital calipers (Starrett®). For such, three measurements of maximum vertical mandibular movement without assistance were made according to the RDC/TMD [14, 15] and the mean of the three readings was calculated. The Patient-Specific Functional Scale was also administered, on which the participant identified up to three activities that are difficult or impossible to execute. A higher mean score (0–10) denotes a greater capacity to perform the activities [24]. The examiners were blinded to the allocation of the participants to the different groups (active or sham photobiomodulation).

Photobiomodulation was administered using a portable cluster of nine diodes (PainAway/PainCure®, Multi Radiance Medical®, Solon, OH, USA): one laser diode (905 nm), four red LED diodes (670 nm), and four infrared LED diodes (875 nm LED). The dose is established by the device, resulting in a total energy delivered of 39.27 J per point and energy density per point (J/cm^2) 99.67. The aperture measures 4 cm^2 , but an adapter with an aperture of 0.394 cm^2 was placed for better application of intraoral therapy. Table 1 lists the photobiomodulation parameters used in the present study. To ensure the blinding of the participants, the same device was used in both groups. For the experimental group, it was necessary to press the button twice (once to switch on the device and once to activate the light). For the sham group, the button was only pressed once to simulate the application. The power of the device was tested with and without the adapter and no loss of power occurred with the use of the adapter.

The volunteer was positioned comfortably in the supine position on an examining table and instructed to remain with her eyes closed while wearing dark protective eyewear. The volunteer was instructed to open her mouth for the positioning of the tip of the photobiomodulation device. The application site and positioning of the therapist were based on the method described by Kalamir et al. (2013) [18] for intraoral myofascial therapy. The therapist sat contralateral to the side to be treated, performed palpation of the region, and inserted the pointer following the orientation of the index finger along the lateral wall of the oropharynx posterior to the last molar in the region of the lateral pterygoid muscle and sphenoid plate (Fig. 1). A 2-min interval with the mouth closed was respected between applications to the right and left hemi-arches to enable the musculature to rest.

The choice of this technique was based on the symptoms reported upon palpation during the clinical examination with the RDC/TMD [10]. Considering the risk of false-positive findings due to the palpation of the medial rather than lateral pterygoid muscle [25], although following all

Table 1 Photobiomodulation parameters

	PainAway/PainCure
Number of lasers	1 super-pulsed infrared
Wavelength of laser (nm)	905
Frequency (Hz)	1000
Mean optic output (mW)	0.9
Peak power (W)	8.5
Total dose (J) (300 s)	0.27
Size of laser tip (cm^2)	0.4
Number of LEDs	4 red
Wavelength of LED (nm)	640
Frequency (Hz)	2
Mean optic output (mW)	15
Dose (J) of each emitter (300 s)	4.5
Total dose (J) (300 s)	18
Size of tip (cm^2)	0.9
Number of LEDs	4 infrared
Wavelength of LED (nm)	875
Frequency (Hz)	16
Mean optic output (mW)	17.5
Dose (J) of each emitter (300 s)	5.25
Total dose (J) (300 s)	21
Size of tip (cm^2)	0.9
Magnetic field (mT)	35
Treatment time (s)	300
Aperture of device with adapter (cm^2)	0.394
Total energy delivered (J)	39.27
Energy density per point (J/cm^2)	99.67

recommendations proposed by Kalamir et al. (2013) [18], the intraoral position referring to the region of the pterygoid muscles was adopted as the application reference based on

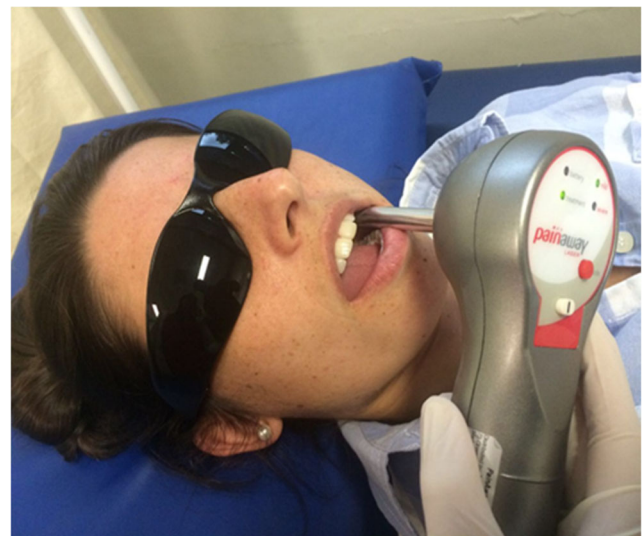

Fig. 1 Application of phototherapy

previous studies [17, 18]. At the end of the study, the patients in the sham group were also submitted to active treatment (Fig. 1; Table 1).

Calculation of sample size

The sample size was calculated considering $\alpha = 0.05$, $1 - \beta = 0.9$ and VAS data described in a study conducted by Pereira et al. (2014) [26]. The calculation was performed using the G*Power program, which determined 15 volunteers for each group.

Statistical analysis

The SPSS program version 17.0 (Chicago, IL, USA) was used for the statistical analyses, with a 5% significance level established for all comparisons. Intention-to-treat analysis was adopted. Histograms were created to test the normality of the data. For outcomes with normal distribution, the data were expressed as mean and standard deviation (SD) values. Adjusted between-group mean differences (MD) and 95% confidence intervals (CI) were calculated with linear mixed models by using group, time, and group-time interaction terms. The Wilcoxon test was used for data with asymmetric distribution (Table 3), considering pre-treatment and post-

treatment conditions for the comparisons. The effect size was calculated using the “*r*” coefficient [27] and interpreted based on the values established by Cohen: small effect (less than $r = 0.12$), moderate effect (approximately $r = 0.33$), and large effect (greater than $r = 0.37$).

Results

A total of 38 participants were recruited for the present study, eight of whom were excluded for different reasons (Fig. 2—flowchart). Thus, 30 women participated in the study (15 in each group). The second column in Table 2 displays the baseline values of the outcome measures. Age was 25.44 years (standard deviation [SD] = 5.76) in the treatment group and 26.55 years (SD = 4.6) in the sham group. Mean body mass index was 21.65 kg/m² (SD = 2.25) in the treatment group and 23.49 kg/m² (SD = 2.13) in the sham group.

Analyzing the clinical effects of the proposed interventions, active photobiomodulation was significantly more effective than sham photobiomodulation after 48 h (MD = -1.57, 95% CI -3.10 to 2.32) and after six sessions (MD = -2.70, 95% CI -4.22 to 1.18). However, considering the minimal clinically important difference [28], active therapy was only better after six sessions. No significant results were found regarding mandibular range of motion (Tables 2 and 3).

Fig. 2 Flowchart

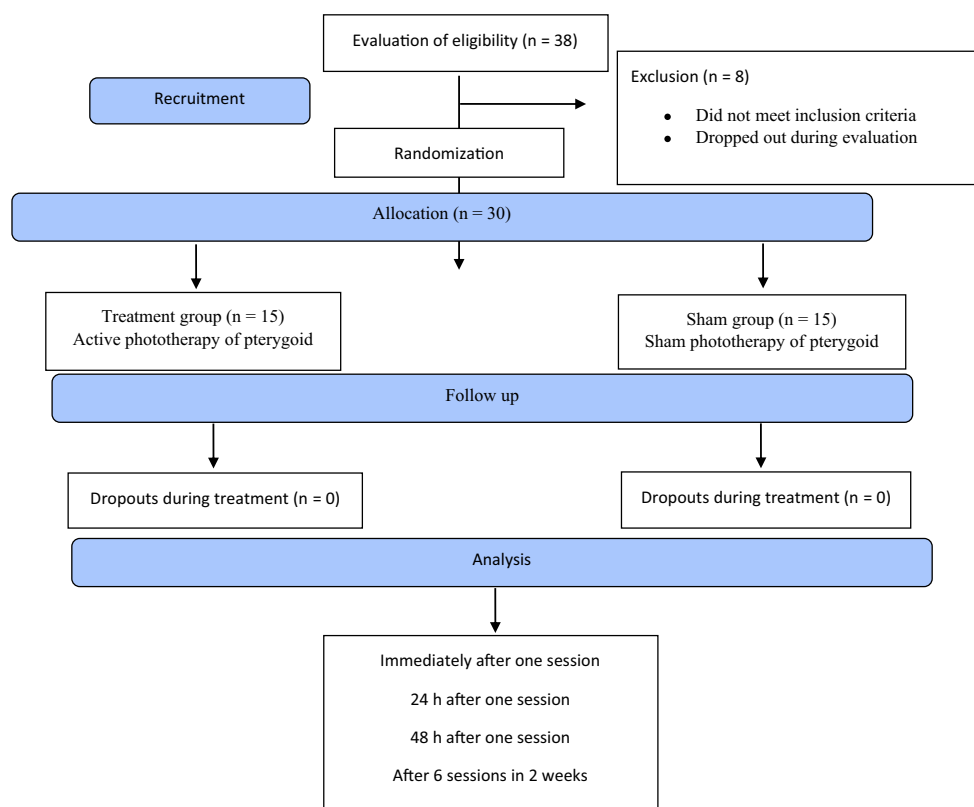


Table 2 VAS scores and mandibular range of motion in treatment and sham groups

Outcome	Time	Treatment group ^a	Sham group ^a	Treatment group—Sham group			
				Pre-P1 ^b	Pre-P24 ^b	Pre-P48 ^b	Pre-P6 ^b
VAS (cm)	Pre	5.75 (1.71)	5.03 (1.14)	-0.92 (-2.45, 0.60)	-1.19 (-2.71, 0.33)	-1.57 (-3.10, 0.04) ^c	-2.70 (-4.22, -1.18) ^c
	P1	4.67 (2.49)	4.87 (1.51)				
	P24	4.25 (2.46)	4.72 (1.51)				
	P48	3.99 (1.93)	4.84 (1.36)				
	P6	1.65 (1.61)	3.62 (1.76)				
ROM opening (mm)	Pre	40.05 (7.50)	39.50 (7.02)	0.45 (-4.78, 5.68)	-2.95 (-8.19, 2.27)	-2.19 (-7.42, 3.04)	-1.20 (-6.43, 4.03)
	P1	43.31 (6.73)	43.95 (5.80)				
	P24	40.59 (9.19)	42.22 (5.42)				
	P48	41.27 (9.34)	43.67 (6.48)				
	P6	44.91 (5.31)	43.91 (4.89)				

VAS, visual analog scale; ROM, range of motion; Pre, baseline; P1, immediately after one session; P24, 24 h after one session; P48, 48 h after one session; P6, after six sessions. ^aData expressed as mean (standard deviation); ^bdata expressed as difference between means (95% confidence interval); ^csignificant difference ($p < 0.05$)

In the analysis of functioning, a significant difference was found between the pre-treatment evaluation and the evaluation after six treatment sessions in the treatment group ($p < 0.04$), with an effect size of 0.5 (Table 4).

Discussion

The aim of the present study was to determine whether photobiomodulation with a combination of different light sources diminishes pain, increases mandibular range of motion, and exerts a positive influence on functioning in women with a diagnosis of myogenous or mixed TMD. Significant differences were found in the analysis of pain comparing the pre-treatment evaluation to the evaluations performed both 48 h after one session and after six treatment sessions ($p < 0.01$). A significant improvement in functioning was also found comparing the pretreatment evaluation to the evaluation performed after six treatment sessions ($p < 0.04$).

These findings are in agreement with data described by Manfredini et al. (2017) [10], Seifi et al. (2017) [11], and Silva (2017) [22], who found improvements in pain following

extraoral photobiomodulation, as well as intraoral manual therapies [17, 18] in the same or nearby region to that employed in the present study. The improvement in functioning may have been influenced by the number of treatment sessions. Manfredini et al. (2017) [10] used nine laser applications to sore muscles over a 3-week period. Seifi et al. (2017) [11] used four sessions, performing a short-term analysis, as in the present investigation. Therefore, further studies are needed to provide solid evidence and precisely determine the best treatment procedures [29].

The reduction in pain may be explained by the reduction in inflammatory cytokines as well as an increase in microcirculation around the irradiated area [22, 30]. Friedman et al. (2009) [20] found that the combination of different wavelengths increases the transfer of electrons, increases the ATP level, and neutralizes reactive oxygen species. Moreover, the increase in local blood flow is capable of reducing the buildup of lactate in the blood and increasing the supply of oxygen to the muscle tissues, thereby reducing muscle fatigue [31] and pain.

Despite the reduction in pain, no changes in the mandibular range of motion were found, which is in agreement with data

Table 3 Within and between group differences (95% confidence intervals) at baseline (pre) and at immediately after one session (P1), 24 h after one session (P24), 48 h after one session (P48), and after six

sessions (P6) for pain intensity (VAS scores) and mandibular range of motion in treatment and sham groups

Outcome	Treatment group—Sham group			
	Pre-P1	Pre-P24	Pre-P48	Pre-P6
VAS (cm)	-0.92 (-2.45, 0.60)	-1.19 (-2.71, 0.33)	-1.57 (-3.10, -0.04)*	-2.70 (-4.22, -1.18)*
ROM opening (mm)	0.45 (-4.78, 5.68)	-2.95 (-8.19, 2.27)	-2.19 (-7.42, 3.04)	-1.20 (-6.43, 4.03)

VAS, visual analog scale; ROM, range of motion; Pre, baseline; P1, immediately after one session; P24, 24 h after one session; P48, 48 h after one session; P6, after six sessions; data expressed as difference between means (95% confidence interval); *significant difference ($p < 0.05$)

Table 4 Median and inter-quartile range (25–75%) for pre-treatment and post-treatment evaluations of functioning

	Pre-treatment	After 6 sessions	<i>p</i> value	Effect size
Group I	13 (9–19)	21 (16–23)	0.04	0.5
Group II	13 (11–13)	13 (10.5–18)	0.46	0.21

GI, experimental group; *GII*, sham group

described in previous studies involving general mandible exercises versus occlusal splint therapy, global posture reeducation, the use of a splint plus counseling, or standard conservative care [32–34]. The number of sessions may not have been sufficient to promote a gain in mandibular range of motion. Therefore, further studies with a longer treatment period are needed.

Trends in the treatment of TMD in recent decades have leaned toward a multimodal approach [35] as well as multi-disciplinary care [8], which is in line with the treatment for other chronic musculoskeletal conditions [18, 21]. Treatment strategies generally suggest faster, less invasive modalities, such as photobiomodulation, which has been gaining ground as a treatment option for different conditions, including TMD [15], as demonstrated in the present study.

Therefore, it may be added that the use of the intraoral photo facilitates the specific application for myofascial pain of intraoral muscles, allowing the amplification of another non-invasive technique by using a customized tip adapted to the equipment, which it demonstrated favorable results in the pain outcome, not being a limiting factor but a gain for intraoral use, expanding possibilities for new studies for TMDs.

Conclusion

Intraoral photobiomodulation involving super-pulsed laser (905 nm) combined with red (640 nm) and infrared (875 nm) light-emitting diodes diminishes pain and improves functioning in women with myogenous temporomandibular disorder.

Limitations

A convenience sample was used composed mainly of university students.

There was difficulty finding eligible volunteers willing to participate in the study during the recruiting process due to lack of availability.

Acknowledgments The authors are grateful to the research team and all participants as well as the University Nove de Julho, and the Brazilian fostering agencies, the State of São Paulo Research Assistance

Foundation, and Coordination for the Improvement of Higher Education Personnel (CAPES).

Funding Funding for this study was provided by Coordination of Improvement of Higher Education Personnel (CAPES).

Compliance with ethical standards

The present randomized, sham-controlled, double-blind clinical trial received approval from the Human Research Ethics Committee of University Nove de Julho, São Paulo, Brazil (certificate number: 42264715.0.0000.5511), and the protocol was registered with clinicaltrials.gov (NCT02839967). This clinical trial was conducted with patients referred from the Department of Physical Therapy of the University Nove de Julho. All volunteers received clarifications regarding the objectives and procedures of the study and those who agreed to participate signed a statement of informed consent.

Conflict of interest Teacher Ernesto Cesar Pinto Leal-Junior receives research support from Multi Radiance Medical (Solon, OH, USA), a laser device manufacturer; he did not have any participation in data collection or data analysis. The remaining authors declare that they have no conflict of interests.

References

- deLeeuw R, Klasser GD (2013) The American Academy of Orofacial Pain. Orofacial pain: guidelines for assessment, diagnosis, and management. Quintessence Publishing, Chicago
- Truelove EL, Sommers EE, LeResche L, Dworkin SF, Von KM (1992) Clinical diagnostic criteria for TMD. New classification permits multiple diagnoses. *J Am Dent Assoc* 123:47–54
- Plesh O, Sinisi SE, Crawford PB, Gansky SA (2005) Diagnoses based on the research diagnostic criteria for temporomandibular disorders in a biracial population of young women. *J Orofac Pain* 19:65–75
- Orlando B, Manfredini D, Bosco M (2006) Efficacy of physical therapy in the treatment of masticatory myofascial pain: a literature review. *Minerva Stomatol* 55(6):355–366
- Gonçalves DA, Dal Fabbro AL, Campos JADB, Bigal ME, Speciali JG (2010) Symptoms of temporomandibular disorders in the population: an epidemiological study. *J Orofac Pain* 24(3):270–278
- Ferreira CLP, Silva MAMR, Felício CM (2016) Sinais e sintomas de desordem temporomandibular em mulheres e homens. *CoDAS* 28(1):17–21. <https://doi.org/10.1590/2317-1782/20162014218>
- Polso H, Napankangas R, Raustia AM (2010) Treatment outcome in patients with TMD – a survey of 123 patients referred to specialist care. *Cranio* 28(3):156–165
- Issa JPM, Silva MAMR, SILVA AMBR (2005) Disfunções temporomandibulares e suas implicações clínicas. *Revista Dor* 6(2):573–578
- Fikácková H, Dostálová T, Navrátil L et al (2007) Effectiveness of low-level laser therapy in temporomandibular joint disorders: a placebo-controlled study. *Photomed Laser Surg* 25(4):297–303
- Manfredini D, Favero L, Cocilovo F, Monici M, Guarda-Nadini L (2017) A comparison trial between three treatment modalities for the management of myofascial pain of jaw muscles: a preliminary study. *Cranio: The Journal of Craniomandibular Practice* 36(2):1–5. <https://doi.org/10.1080/08869634.2017.1349571>
- Seifi M, Ebadifar A, Kabiri S, Badiie MR, Abdolazimi Z, Amdjadi P (2017) Comparative effectiveness of low level laser therapy and

- transcutaneous electric nerve stimulation on temporomandibular joint disorders. *J Lasers Med Sci* 8(1):27–31
12. Khalighi HR, Mortazavi H, Mojahedi SM, Marhabi SA, Abbasabadi FM (2016) Low level laser therapy versus pharmacotherapy in improving myofascial pain disorder syndrome. *J Lasers Med Sci* 7(1):45–50. <https://doi.org/10.15171/jlms.2016.10>
 13. Kelencz CA, Muñoz IS, Amorim CF, Nicolau RA (2010) Effect of low-power gallium-aluminum-arsenium noncoherent light (640 nm) on muscle activity: a clinical study. *Photomed Laser Surg* 28(5):647–652
 14. Hage YE, Politti F, Sousa DFM, Herpich CM et al (2013) Effect of facial massage on static balance in individuals with temporomandibular disorder - a pilot study. *Int J Ther Massage Bodywork* 6:6–11
 15. Herpich CM, Leal-Junior ECP, Gomes CAFP et al (2017) Immediate and short-term effects of phototherapy on pain, muscle activity, and joint mobility in women with temporomandibular disorder: a randomized, double-blind, placebo-controlled, clinical trial. *Disabil Rehabil* 1:1–7
 16. Herpich CM, Gomes CAFP, Gloria IPS et al (2018) Evaluation of pain threshold upon palpation of the masticatory muscles in women with temporomandibular disorder according to the Research Diagnostic Criteria of Temporomandibular Disorders. *Rev CEFAC* 20(2):175–181
 17. Barriere P, Zink S, Riehm S, Kahn JL, Veillon F, Wilk A (2009) Massage du muscle ptérygoïdien latéral dans le SADAM aigu Massage of the lateral pterygoid muscle in acute TMJ dysfunction syndrome. *Rev Stomatol Chir Maxillofac* 110(2):77–80. <https://doi.org/10.1016/j.stomax.2008.05.010>
 18. Kalamir A, Graham P, Vitiello AL, Bonello R, Pollard H (2013) Intra-oral myofascial therapy versus education and self-care in the treatment of chronic, myogenous temporomandibular disorder: a randomised, clinical trial. *Chiropr Man Therap* 21:17
 19. Fujita S, Iizuka T, Dauber W (2001) Variation of heads of lateral pterygoid muscle and morphology of articular disc of human temporomandibular joint—anatomical and histological analysis. *J Oral Rehabil* 28:560–571
 20. Friedmann H, Lipovsky A, Nitzan Y, Lubart R (2009) Combined magnetic and pulsed laser field produce synergistic acceleration of cellular electron transfer. *Laser Ther* 18:137–141
 21. Leal Junior ECP, Johnson DS, Saltmarche A, Demchak T (2014) Adjunctive use of combination of super-pulsed laser and light-emitting diodes phototherapy on nonspecific knee pain: double-blinded randomized placebo-controlled trial. *Lasers Med Sci* 29:1839–1847
 22. Silva MM, Albertine R, Carvalho PTC, Leal-Junior ECP, Bussadori SK, Vieira SS, Bocalini DS, Oliveira VS, Grandinetti V, Silva JÁ, Serra AJ (2017) Randomized, blinded, controlled trial on effectiveness of photobiomodulation therapy and exercise training in the fibromyalgia treatment. *Lasers Med Sci*. <https://doi.org/10.1007/s10103-017-2388-2>
 23. Ferreira-Valente MA, Pais-Ribeiro JL, Jensen MP (2011) Validity of four pain intensity-rating scales. *Pain* 152(10):2399–2404
 24. Horn KK, Jennings S, Richardson G, Vliet DV, Hefford C, Abbott JH (2012) The patient-specific functional scale: psychometrics, clinimetrics, and application as a clinical outcome measure. *J Orthop Sports Phys Ther* 42(1):30–42. <https://doi.org/10.2519/jospt.2012.3727>
 25. Stratmann U, Mokrys K, Meyer U, Kleinheinz J, Joos U, Dirksen D et al (2000) Clinical anatomy and palpability of the inferior lateral pterygoid muscle. *J Prosthet Dent* 83:548–554
 26. Pereira TS, Flecha OD, Guimarães RC, de Oliveira D, Botelho AM, Ramos Glória JC et al (2014) Efficacy of red and infrared lasers in treatment of temporomandibular disorders—a double-blind, randomized, parallel clinical trial. *Cranio J Craniomandib Pract* 32(1):51–56
 27. Cohen J (1988) *Statistical power analysis for the behavioral sciences*, 2nd edn. Erlbaum, Hillsdale
 28. Arnijo-Olivo S, Pitance L, Neto VSF, Thie N, Michelotti A (2016) Effectiveness of manual therapy and therapeutic exercise for temporomandibular disorders: systematic review and meta-analysis. *Phys Ther* 96:9–25. <https://doi.org/10.2522/ptj.20140548>
 29. Chen J, Huang Z, Ge M, Gao M (2015) Efficacy of low-level laser therapy in the treatment of TMDs: a meta-analysis of 14 randomised controlled trials. *J Oral Rehabil* 42(4):291–299
 30. Bjordal JM (2006) Photoradiation in acute pain: a systematic review of possible mechanisms of action and clinical effects in randomized placebo-controlled trials. *Photomed Laser Surg* 24(2):158–168
 31. Miranda EF, Leal Junior ECP, Marchetti PH, Dal Corso S (2014) Acute effects of light emitting diodes therapy (LEDT) in muscle function during isometric exercise in patients with chronic obstructive pulmonary disease: preliminary results of a randomized controlled trial. *Lasers Med Sci* 29:359–365
 32. Grace EG, Sarlani E, Reid B (2002) The use of an oral exercise device in the treatment of muscular TMD. *Cranio* 20(3):204–208
 33. de Felício CM, de Oliveira MM, da Silva MA (2010) Effects of orofacial myofunctional therapy on temporomandibular disorders. *Cranio* 28(4):249–259
 34. Niemela K, Korpela M, Raustia A, Ylostalo P, Sipila K (2012) Efficacy of stabilisation splint treatment on temporomandibular disorders. *J Oral Rehabil* 39(11):799–804
 35. Freire AB, De Nardi AT, Bouffleur J, Chiodelli L, Pasinato F, Corrêa ECR (2014) Multimodal physiotherapeutic approach: effects on the temporomandibular disorder diagnosis and severity. *Fisioterapia em Movimento* 27(2):219. <https://doi.org/10.1590/0103-5150.027.002.AO07>

Publisher's note Springer Nature remains neutral with regard to jurisdictional claims in published maps and institutional affiliations.