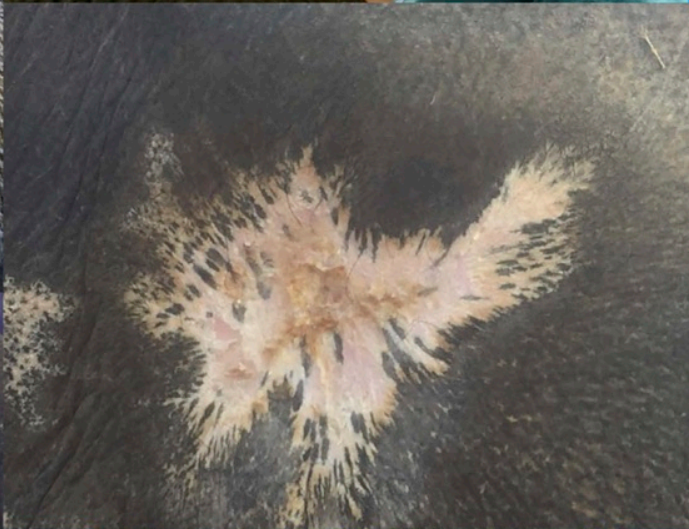
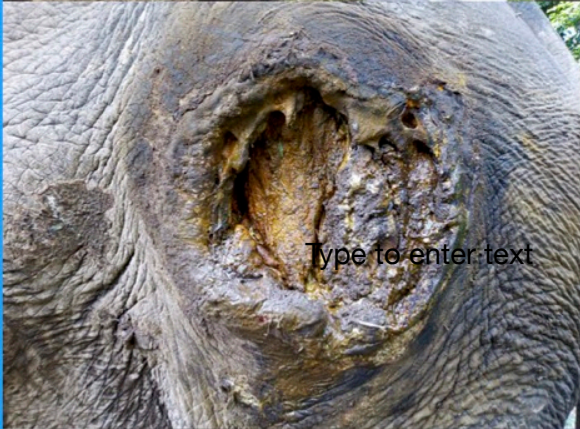

Sita gets Multi Radiance help by Dr. Trish London to close necrotic wounds



Sita Kali, 40 yo female asian elephant sustained a large pressure (bed) sore after she collapsed twice over the summer after being injured by another elephant while giving rides to tourists. Due to their massive size and weight, anytime an elephant is down on their side there can be a variety of injuries that may happen. It is essential to get them up and on their feet again as soon as possible. The Multi Radiance ACTIVet laser was used daily for 3 months along with topical medications to help successfully completely heal the wound. Elephants are known to be very slow healers and I think the use of the laser helped heal her wound completely and quicker than expected with traditional methods. Sita continues to recover from all of her injuries and has been officially retired.

Sita Kali is a blind captive female Asian elephant in her forties who had been giving safari rides in Nepal for the past three years. Prior to this she was working in India. Sita was hit and knocked over by another elephant while giving rides in March 2018. After that she was kept on exercise restriction and was very weak and shaking/trembling in her hind legs when walking and was no longer lying down to sleep.

On June 19, 2018, Sita collapsed and was down on her left side down for three days. It was reported she had not been eating or drinking well for days, up to one week before she collapsed. (See picture 1)

On June 21st, she was lifted up on her feet again and was kept in a sling to support her. After being on her side for three days her left ear was paralyzed and the ear tip had necrosis, she had a large pressure wound on her left hip and many scrapes all over her body, a large amount of ventral edema and vulvar edema, and a very stiff and swollen left carpus. Due to their massive size and weight anytime an elephant is down there can be a variety of injuries. It is essential to get them up and on their feet again as soon as possible. (picture 2 &3) Sita was then placed in a sling to help support her to stand.

July 12th, Sita collapsed again in the hind end while in her harness supporting her chest . She was again on her left side for three days until July 14th when a crane was used to get her up she again. She again had edema of her left rear leg, vulvar edema and the pressure sore on her left hip was larger with dead tissue noted.

On July 29th a very large necrotic wound opened on her left hip and daily cleaning and debriding of dead tissue was performed of the wound and injectable antibiotics and meloxicam and vitamins were given. (picture 3 & 4)

On August 9th I returned to Nepal and continued cleaning the wound every other day and treating with topical antibiotic cream, placenta cream, turmeric, hymax (local Ayurvedic) antibiotic/fungal/parasite and fly cream and laser treatments daily (Setting 2 with blue light for 10 minutes). (Picture 4 &5)

Weekly measurements and pictures were taken of the wound

8/9 First laser treatment

10/17 as the wound became smaller I decreased treatment time to 5mins setting 2 with blue light

11/4 final laser treatment

January 4th 2019 wound has completely healed

1/21/19 Sita has been officially retired and will never work again. Sita will be moving to a retirement facility near the forest in Nepal. If you would like to help support her retirement (food and continued medical care) please contact **Dr. London pm london@yahoo.com or Stand Up 4 Elephants su4e.org** to make a donation. Volunteers are also accepted.